

CASE REPORTS



Retinal morphological and functional response to Idebenone therapy in Leber hereditary optic neuropathy

MARIA FILOFTEIA MERCUȚ¹⁾, CORNELIA ANDREEA TĂNASIE²⁾, ALEXANDRA OLTEA DAN²⁾,
ANDREEA MIHAELA NICOLCESCU¹⁾, OANA MARIA ICĂ³⁾, CARMEN LUMINIȚA MOCANU¹⁾,
ALIN ȘTEFAN ȘTEFĂNESCU-DIMA¹⁾

¹⁾Department of Ophthalmology, Faculty of Medicine, University of Medicine and Pharmacy of Craiova, Romania

²⁾Department of Physiology, Faculty of Medicine, University of Medicine and Pharmacy of Craiova, Romania

³⁾Department of Dermatology, Faculty of Medicine, University of Medicine and Pharmacy of Craiova, Romania

Abstract

Leber hereditary optic neuropathy (LHON) is a mitochondrial disease leading to optic atrophy due to degeneration of the retinal ganglion cell. A curative treatment is not available at the moment, but a new antioxidant drug, Idebenone, is expected to reduce the progression of the disorder. Two male patients, genetically confirmed with LHON, were clinically, morphologically, and electrophysiologically evaluated, before and three, six, nine and 12 months after starting the treatment. The patient with 3460G>A mutation in mitochondrially-encoded nicotinamide adenine dinucleotide, reduced form (NADH):ubiquinone oxidoreductase core subunit (*mtND1*) gene showed an improvement in visual acuity, visual field, and visual evoked potentials with no effect on morphological examinations, while the patient with 11778G>A mutation in *mtND4* gene showed no functional, nor morphological recovery after one year of treatment. This study demonstrates that Idebenone, depending on the genetic profile of the disease, may be effective in functional improvement in patients with LHON.

Keywords: LHON, Idebenone, optical coherence tomography.

Introduction

Leber hereditary optic neuropathy (LHON) was first described by the German ophthalmologist Theodor Leber, in 1871, after observing acute and irreversible visual acuity (VA) loss in both eyes, in young men from four families [1]. In 1972, Erikson demonstrated that LHON is a mitochondrial disorder characterized by mutations in the mitochondrial genome [mitochondrial deoxyribonucleic acid (mtDNA)], with a maternal mode of inheritance [2]. Further studies proved that the affected genes are nicotinamide adenine dinucleotide, reduced form (NADH):ubiquinone oxidoreductase core subunit (*ND*)4, *ND1* and *ND6*, genes that are coding for a polypeptide of the electron transport chain, complex I, which leads to energy reduction in the retinal ganglion cells (RGCs), causing apoptosis of these cells [3]. Another mechanism that causes RGC death is the dysfunction of glutamate transportation system, leading to elevated levels of oxidative stress [4]. The responsible mutations for almost 95% of LHON cases are *G3460A* (*ND1*) [5], *G11778A* (*ND4*) [6] and *T14484C* (*ND6*) [7]. These mutations lead to degeneration of the RGCs, causing optic atrophy in the advanced stage of the disease.

Clinically, the disease evolves in four stages: asymptomatic, presymptomatic, acute and chronic [8]. Patients present with acute or subacute decreased VA, which is painless, bilateral, and usually asymmetrical. In the acute stage, ophthalmoscopy reveals disk hyperemia, swelling of the nerve fiber layer, vascular tortuosity of the central

retinal vessels, retinal telangiectasia [8], which in six to eight weeks turns into optic disc pallor, more obvious temporally secondary to initial axonal degeneration in papillomacular bundle [9]. Visual field testing shows a central scotoma, which enlarges in size and density as VA decreases [10].

Until 2015, no specific treatments were available for LHON. Idebenone is a benzoquinone which can prevent the apoptosis of RGC [11] by its antioxidant effects and its capability to bypass complex I of the mitochondrial respiratory chain and to transfer electrons straight to complex III [12]. Through this process, Idebenone can generate adenosine triphosphate (ATP) for RGCs that are still viable, but dysfunctional. The hydrophilicity/lipophilicity structure of short chain benzoquinone is the key to ATP generation under condition of complex I dysfunction [11, 13]. The effect of Idebenone treatment in LHON patients is the recovery of dormant, but non-apoptotic RGC by serving as an electron carrier in the mitochondrial respiratory chain [14].

Aim

The aim of our study was to evaluate the effects of Idebenone in two patients genetically confirmed with LHON.

Patients, Materials and Methods

Two male patients aged 15 and 11 years old, genetically confirmed with LHON mutations, underwent complete ophthalmological examination before and three, six and

nine months after we initiated treatment with Idebenone 900 mg/day. The ophthalmological examination included VA, retinal photography, visual field tests, optical coherence tomography (OCT), flash and pattern-reversal visual evoked potentials (VEPs).

VA was measured according to *Early Treatment Diabetic Retinopathy Study* (ETDRS) charts. For visual field testing, we used the 2010 Carl Zeiss Meditec and Optopol Technology Sp. Z. o.o systems and we evaluated the 30-2 central threshold test. Retinal photography and OCT were obtained by using the TopCon system. Regarding the OCT scans, we analyzed the retinal nerve fiber layer (RNFL) in nasal (N), temporal (T), superior (S) and inferior (I) quadrants, and macular ganglion cell layers (GCLs) thickness. VEPs were recorded with Metrovision MonPack One system, and we analyzed the presence, amplitude, and latency of P100 wave in pattern-reversal VEP and of P2 wave in flash VEP.

The inclusion criteria were (i) the presence of a LHON mutation, (ii) the presence of a clinical sign or symptom of the disease: painless decreased VA, decreased VA below 1 logarithm of the minimum angle of resolution (*logMAR*) in the first 12 months from clinical onset, central/cecocentral scotoma, dyschromatopsia, optic nerve pseudo-edema, (iii) clinical onset less than 60 months, (iv) no response to oral glucocorticoids for 15–30 days, (v) signed informed consent.

The exclusion criteria were (i) clinical onset over 60 months, (ii) patients with other neuropathies or degenerative diseases, (iii) no signed informed consent.

Our study respected the tents of the Declaration of Helsinki and written informed consent was signed by the subjects and their parents.

Case presentations

Case No. 1

A 15-year-old male patient presented in the Department of Ophthalmology, Emergency County Hospital, Craiova, Romania for severe drop of VA in both eyes, worse in the right eye (RE), started two months earlier. On our clinical examination, the best corrected visual acuity (BCVA) was 0.08 in his RE and 0.2 in his left eye (LE), with normal intraocular pressure (IOP). Biomicroscopically, he presented a normal aspect of the anterior segment but on ophthalmoscopic examination, we observed hyperemic optic discs with telangiectatic and tortuous peripapillary vessels and edematous appearance of the RNFL (Figure 1A). The visual field test showed a central scotoma in both eyes, denser in the RE (Figure 2), and the OCT detected RNFL swelling in both eyes (Figure 3A). Brain magnetic resonance imaging (MRI) was normal. In his family, the maternal uncles were known with optic atrophy since childhood. We considered optic neuritis as a possible diagnosis, so we started the general corticotherapy to which he was unresponsive. Due to his clinical aspect and family history, we asked for LHON genetic testing, and we detected the *3460G>A* mutation. His mother was also *G3460A* positive and asymptomatic. At that moment, there was no accessible treatment for LHON in our country. Fifteen months later, the VA decreased

to counting fingers at 1 m RE and counting fingers at 2 m LE and ophthalmoscopic examination revealed bilateral optic atrophy (Figure 1B). The OCT revealed important loss of RNFL (Figure 3B), and ganglion cells (Figure 4A) and visual field test showed central scotoma in both eyes (Figure 5A). The VEPs detected no specific complex in pattern-reversal responses and a delayed and decreased P2 wave in flash recordings (Figure 6A). Treatment with Idebenone 900 mg daily was initiated and we evaluated the patient at three, six, nine and 12 months. At 12-month examination, the VA was 0.8 RE and 0.4 LE. The visual field test detected important fenestration of the central scotoma in both eyes (Figure 5B). The flash VEPs revealed a P2 wave with a slight increase in amplitude in both eyes, and absent response in pattern-reversal stimulation (Figure 6B). The OCT scans showed no improvement (Figures 3C and 4B). With these results, the patient was eligible for continuing the treatment for up to 24 months, being evaluated every three months. The VA improved up to 1 in his RE and 0.6 in his LE. The central scotoma continued to decrease in density (Figure 5C). Regarding the VEPs, the P2 wave showed an increase in amplitude and decrease in latency (Figure 6C), but the OCT scans remained unchanged (Figures 3D and 4C).

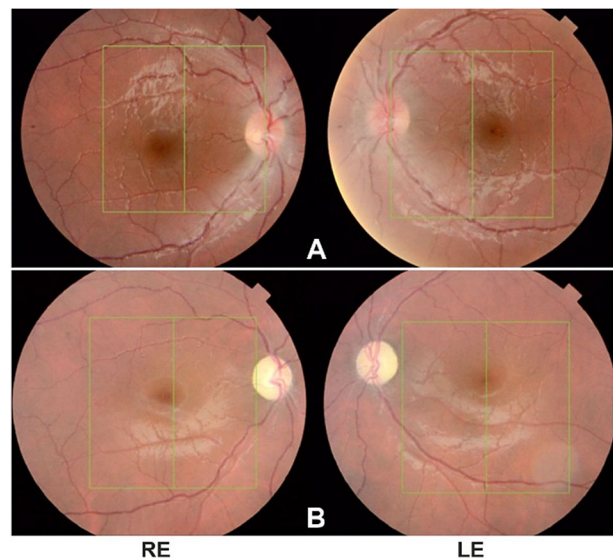


Figure 1 – Case No. 1. Fundus aspect at presentation (A) showing hyperemic optic disc, tortuous peripapillary vessels and edematous appearance of the retinal nerve fiber layer; before treatment initiation (B) showing optic atrophy. LE: Left eye; RE: Right eye.

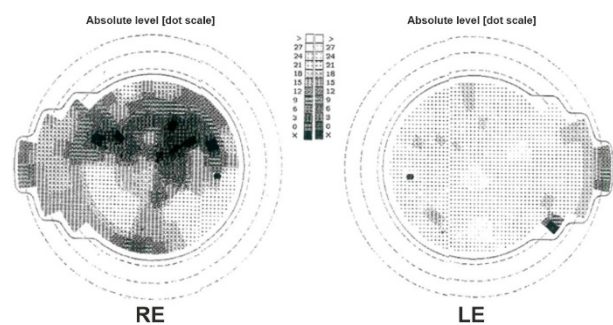


Figure 2 – Case No. 1. Visual field aspect at presentation showing central scotoma, denser in the RE. LE: Left eye; RE: Right eye.

Figure 3 – Case No. 1. OCT aspect, RNFL thickness: at presentation (A) showing increased thickness of the RNFL; before treatment initiation (B) showing decreased thickness of the RNFL; after 12 months of treatment (C) showing decreased thickness of RNFL; after 24 months of treatment (D) showing decreased RNFL thickness, but relatively stable compared to previous examinations. I: inferior; LE: Left eye; N: Nasal; OCT: Optical coherence tomography; RE: Right eye; RNFL: Retinal nerve fiber layer; S: Superior; T: Temporal.

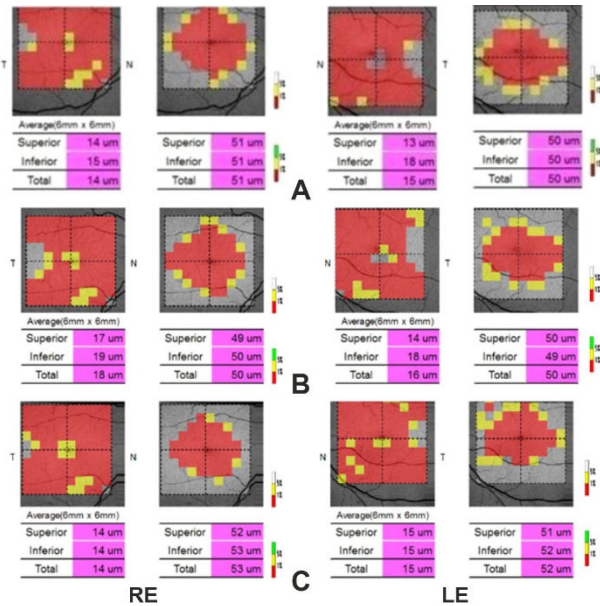
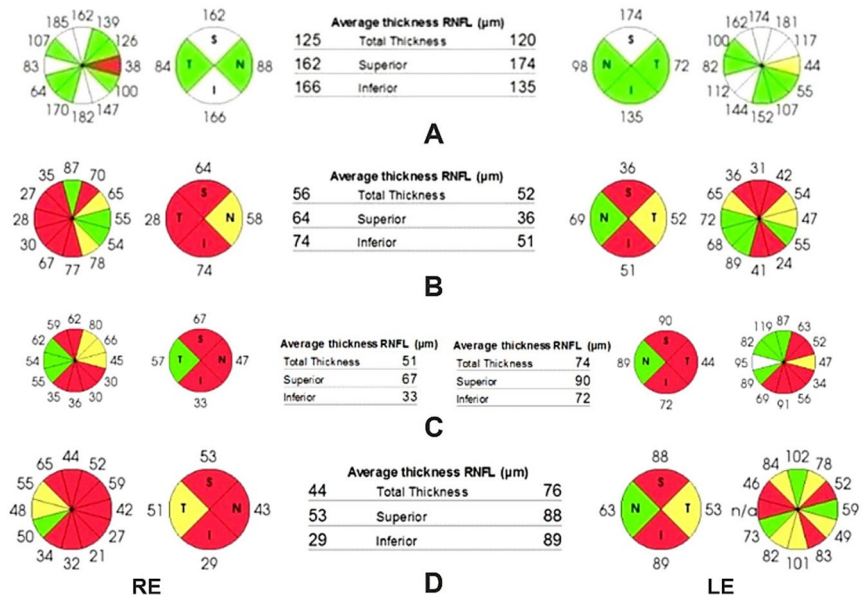


Figure 4 – Case No. 1. OCT aspect, GCL thickness: before treatment initiation (A) showing severely decreased thickness of GCL that remains relatively stable after 12 months of treatment (B) and after 24 months of treatment (C). GCL: Ganglion cell layer; LE: Left eye; N: Nasal; OCT: Optical coherence tomography; RE: Right eye; T: Temporal.

Case No. 2

A 11-year-old male patient presented in our Emergency Department for bilateral marked decrease of VA. On clinical examination, the BCVA was counting fingers at 2 m in his RE and counting fingers at 3 m in his left eye, normal IOP and normal aspect of the anterior segment. The fundoscopic aspect revealed pale and plane papillae, with net contour and physiological excavation of both eyes (Figure 7). The visual field detected central scotoma (Figure 8A) and the VEPs showed a delayed and decreased P2 wave in flash stimulation and no response to pattern-reversal stimulation (Figure 9A). The OCT presented bilateral atrophy of RNFL (Figure 10A) and reduced thickness of GCL (Figure 11A). Brain MRI scans were normal. The corticoid therapy was




Figure 5 – Case No. 1. Visual field aspect before treatment initiation (A) showing very dense central scotoma; after 12 months of treatment (B) showing fenestration of the central scotoma that continues to decrease in density after 24 months of treatment (C). LE: Left eye; RE: Right eye.

initiated for 14 days, with no effect, and we decided on genetic testing for LHON. The *G11778A* mutation was identified, and we started the treatment with Idebenone 900 mg/day, with evaluation at every three months. After three months of treatment, there was no change in VA, visual field, OCT and VEPs. At the 12-month evaluation, the VA was counting fingers at 2 m in both eyes and the visual field showed an increased density of the scotoma in both eyes (Figure 8B). The OCT (Figures 10B and 11B) and VEPs (Figure 9B) had the same aspect compared to the moment of presentation.

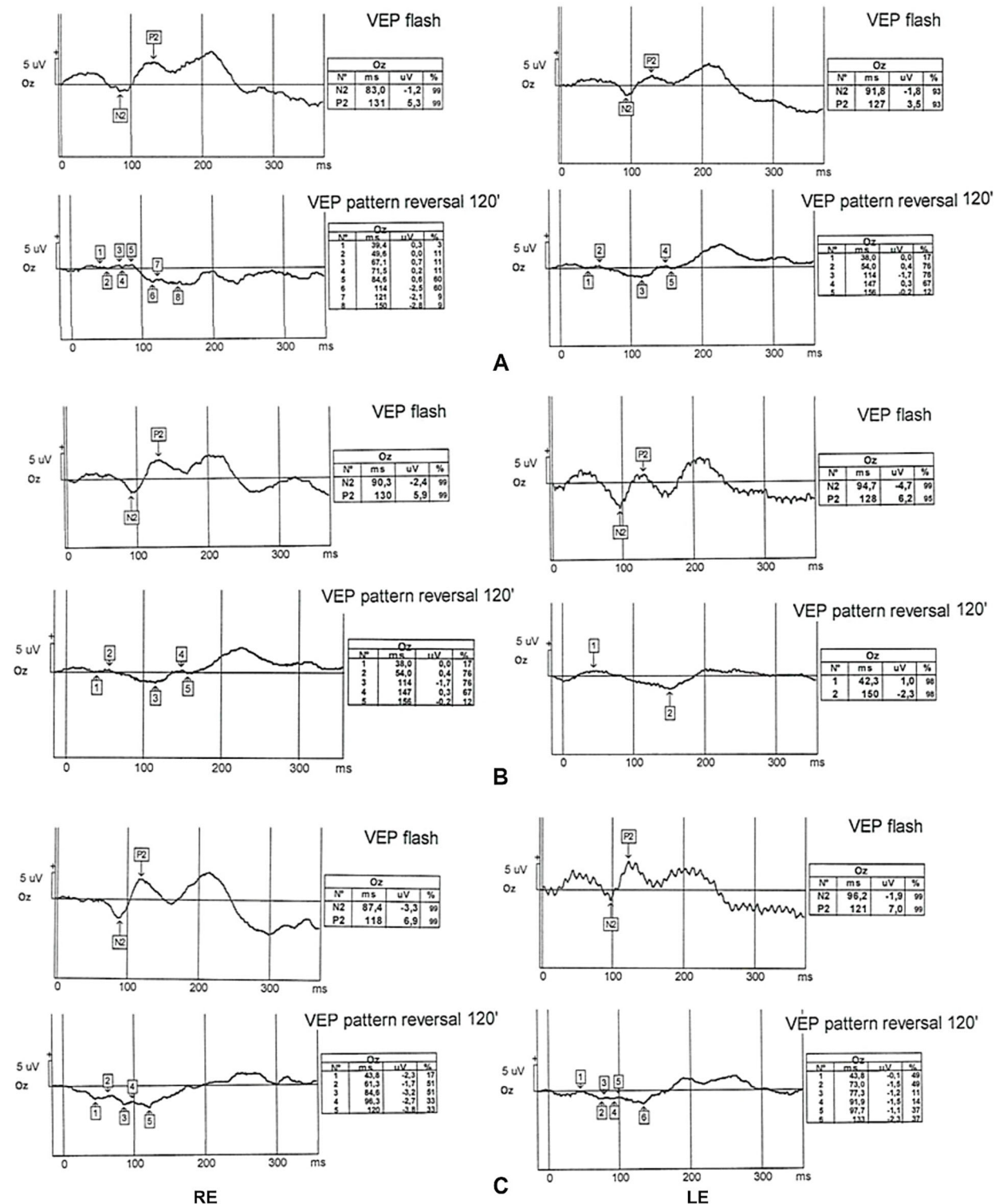


Figure 6 – Case No. 1. Flash and pattern-reversal 120' VEPs before treatment initiation (A) showing a delayed and decreased P2 wave in flash recording and no specific complex in pattern-reversal 120'; after 12 months of treatment (B) showing an increased P2 wave and absent response in pattern-reversal stimulation; after 24 months of treatment (C) showing an increase in amplitude and decrease in latency of P2 wave, with no response in pattern-reversal 120'. LE: Left eye; RE: Right eye; VEP: Visual evoked potential.

Discussions

We present two cases of LHON in two young male patients, with different clinical patterns and genetic profile. Both patients were treated with Idebenone 900 mg daily, when the treatment became available, and we analyzed the

clinical, morphological, and functional response every three months.

LHON is a mitochondrial disease which affects the retinal GCL through impaired glutamate transport and reduction of ATP production leading to increased production of reactive oxygen species [8]. Idebenone is the first approved

treatment for LHON, due to its action of generating cellular energy through its electron carrier and antioxidant effects [13]. Its efficacy was demonstrated by *Rescue of Hereditary Optic Disease Outpatient Study* (RHODOS) [15] and it is considered that visual improvement is strongly correlated with treatment initiation in the acute or subacute stages of the disease [16]. Klopstock *et al.* showed in their study that patients with *G3460A* and *G11778A* mutations are more responsive to Idebenone treatment compared to patients with *T14484C* mutation, which may improve spontaneously [15].

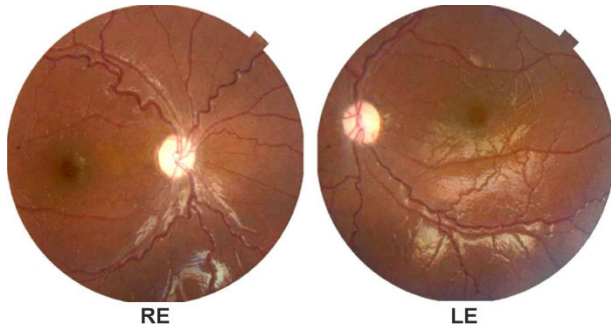


Figure 7 – Case No. 2. Fundus aspect before treatment initiation showing pale, plane papillae. LE: Left eye; RE: Right eye.

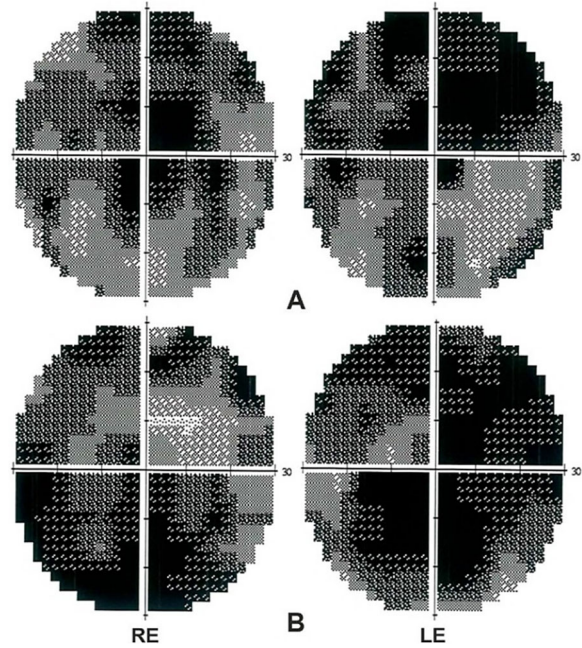


Figure 8 – Case No. 2. Visual field aspect before treatment initiation (A) showing central scotoma that increased in density after 12 months of treatment (B). LE: Left eye; RE: Right eye.

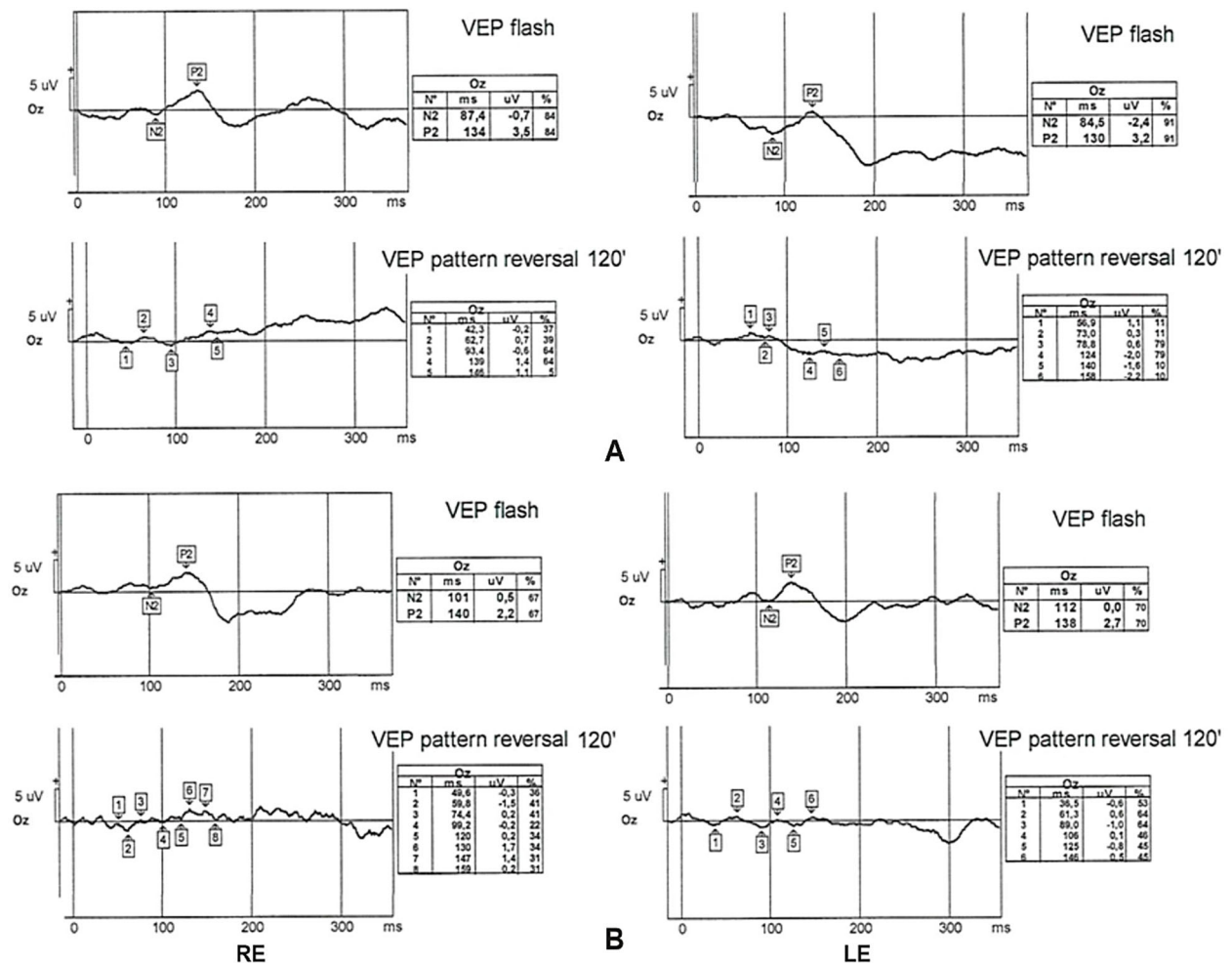


Figure 9 – Case No. 2. Flash and pattern-reversal 120' VEPs before treatment initiation (A) showing delayed and decreased P2 wave in flash stimulation and no response to pattern-reversal stimulation with no improvement after 12 months of treatment (B). LE: Left eye; RE: Right eye; VEP: Visual evoked potential.

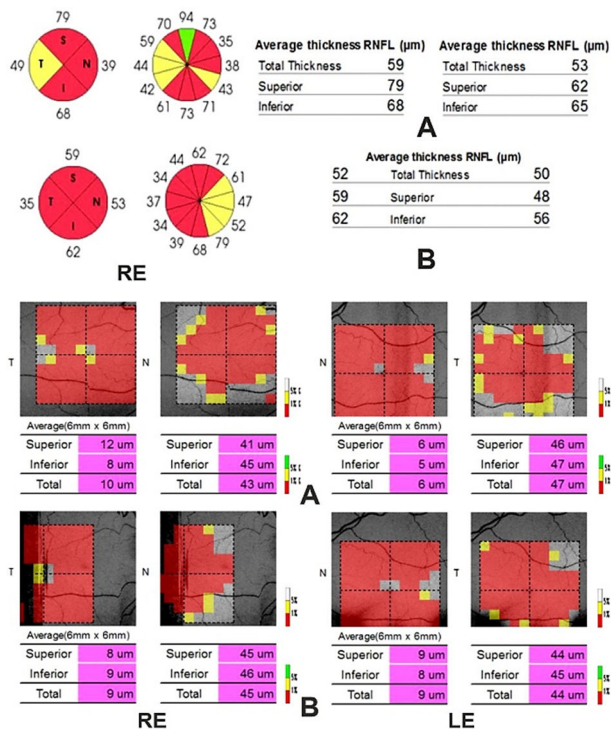


Figure 11 – Case No. 2. OCT aspect, GCL thickness before treatment initiation (A) showing very reduced thickness of GCL with no improvement after 12 months of treatment (B). GCL: Ganglion cell layer; LE: Left eye; N: Nasal; OCT: Optical coherence tomography; RE: Right eye; T: Temporal.

In our first case, the patient was positive for *G3460A* mutation, but at the moment of diagnosis there was no available treatment in our country, so we started the therapy 15 months later, when Idebenone was approved for LHON. We observed an improvement in VA after three months of treatment with slight fenestration of the central scotoma. After 12 months, apart from VA and visual field improvement, we obtained an increased P2 wave in flash VEPs, with a stable aspect of funduscopy and OCT. We continued the treatment for 12 months, with good results in VA, visual field and VEPs, but unchanged ophthalmoscopy and OCT aspect. This case of LHON treated with Idebenone shows an improvement in all functional exams: VA, visual field and VEPs, with no effect on morphological investigations (funduscopy and OCT). Our findings are consistent with the Idebenone mechanism of action, showing that it can restore dormant, but viable ganglion cells [13, 17]. Even if the treatment was started 15 months after the clinical onset, we obtained very good results during the treatment, but also at the final examinations. This data is different from other studies results, which consider that best results are obtained if the treatment is initiated in the acute or subacute stage of the disease [13, 16]. Regarding the mutation for which the patient was positive, our findings are also similar to a study which consider that *G3460A* has a bad prognosis without treatment, but a good response to Idebenone [17, 18]. Both the patient and his asymptomatic mother are evaluated at every three months.

The second patient was diagnosed in the chronic stage of the disease, even if he affirmed that the VA started to decrease approximately two months before presentation. There was no improvement in functional or in morpho-

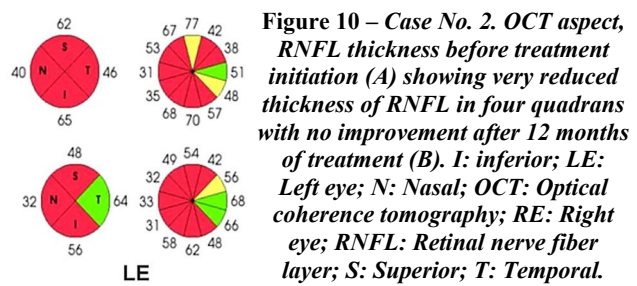


Figure 10 – Case No. 2. OCT aspect, RNFL thickness before treatment initiation (A) showing very reduced thickness of RNFL in four quadrants with no improvement after 12 months of treatment (B). I: inferior; LE: Left eye; N: Nasal; OCT: Optical coherence tomography; RE: Right eye; RNFL: Retinal nerve fiber layer; S: Superior; T: Temporal.

logical examinations during or at the end of treatment with Idebenone, even if the treatment was started shortly after presentation. Although the patient was positive for *G11778A* mutation, which is considered to have a good prognosis under treatment [16, 19, 20], we obtained no recovery in VA, visual field, VEP, funduscopy, nor OCT after 12 months of therapy, so we stopped Idebenone treatment. The 19-year-old brother was also positive for *G11778A* mutation, so we examine him every three months for an early diagnosis and proper initiation of treatment.

Conclusions

Our cases show that Idebenone may be a valuable therapy in maintaining and improving the visual function, in LHON patients. Regarding the retinal morphological aspect, the thickness of both the GCL and the RNFL remains relatively stable. The genetic profile and the early initiation of the therapy may influence Idebenone efficiency.

Conflict of interests

The authors declare that they have no conflict of interests.

Authors' contribution

Maria Filofteia Mercuț and Alexandra Oltea Dan have equally contributed to this paper.

References

- Meyerson C, Van Stavern G, McClelland C. Leber hereditary optic neuropathy: current perspectives. *Clin Ophthalmol*, 2015, 9:1165–1176. <https://doi.org/10.2147/OPHT.S62021> PMID: 26170609 PMID: PMC4492634
- Erickson RP. Leber's optic atrophy, a possible example of maternal inheritance. *Am J Hum Genet*, 1972, 24(3):348–349. PMID: 5063796 PMID: PMC1762279
- Kirches E. LHON: Mitochondrial mutations and more. *Curr Genomics*, 2011, 12(1):44–54. <https://doi.org/10.2174/138920211794520150> PMID: 21886454 PMID: PMC3129042
- Zhuo Y, Luo H, Zhang K. Leber hereditary optic neuropathy and oxidative stress. *Proc Natl Acad Sci U S A*, 2012, 109(49):19882–19883. <https://doi.org/10.1073/pnas.1218953109> PMID: 23197830 PMID: PMC3523847
- Huoponen K, Vilkki J, Aula P, Nikoskelainen EK, Savontaus ML. A new mtDNA mutation associated with Leber hereditary optic neuroretinopathy. *Am J Hum Genet*, 1991, 48(6):1147–1153. PMID: 1674640 PMID: PMC1683111
- Wallace DC, Singh G, Lott MT, Hodge JA, Schurr TG, Lezza AM, Elsas LJ 2nd, Nikoskelainen EK. Mitochondrial DNA mutation associated with Leber's hereditary optic neuropathy. *Science*, 1988, 242(4884):1427–1430. <https://doi.org/10.1126/science.3201231> PMID: 3201231
- Johns DR, Neufeld MJ, Park RD. An ND-6 mitochondrial DNA mutation associated with Leber hereditary optic neuropathy. *Biochem Biophys Res Commun*, 1992, 187(3):1551–1557. [https://doi.org/10.1016/0006-291x\(92\)90479-5](https://doi.org/10.1016/0006-291x(92)90479-5) PMID: 1417830
- Fraser JA, Bioussé V, Newman NJ. The neuro-ophthalmology of mitochondrial disease. *Surv Ophthalmol*, 2010, 55(4):299–334. <https://doi.org/10.1016/j.survophthal.2009.10.002> PMID: 20471050 PMID: PMC2989385

- [9] Yu-Wai-Man P, Griffiths PG, Chinnery PF. Mitochondrial optic neuropathies – disease mechanisms and therapeutic strategies. *Prog Retin Eye Res*, 2011, 30(2):81–114. <https://doi.org/10.1016/j.preteyeres.2010.11.002> PMID: 21112411 PMCID: PMC3081075
- [10] Theodorou-Kanakari A, Karampitanis S, Karageorgou V, Kampourelli E, Kapasakis E, Theodossiadis P, Chatziralli I. Current and emerging treatment modalities for Leber's hereditary optic neuropathy: a review of the literature. *Adv Ther*, 2018, 35(10):1510–1518. <https://doi.org/10.1007/s12325-018-0776-z> PMID: 30173326 PMCID: PMC6182630
- [11] Peragallo JH, Newman NJ. Is there treatment for Leber hereditary optic neuropathy? *Curr Opin Ophthalmol*, 2015, 26(6):450–457. <https://doi.org/10.1097/ICU.0000000000000212> PMID: 26448041 PMCID: PMC4618295
- [12] Gueven N, Woolley K, Smith J. Border between natural product and drug: comparison of the related benzoquinones Idebenone and coenzyme Q10. *Redox Biol*, 2015, 4:289–295. <https://doi.org/10.1016/j.redox.2015.01.009> PMID: 25625583 PMCID: PMC4803797
- [13] Yu-Wai-Man P, Soiferman D, Moore DG, Burté F, Saada A. Evaluating the therapeutic potential of Idebenone and related quinone analogues in Leber hereditary optic neuropathy. *Mitochondrion*, 2017, 36:36–42. <https://doi.org/10.1016/j.mito.2017.01.004> PMID: 28093355 PMCID: PMC5644719
- [14] Fantini M, Asanad S, Karanjia R, Sadun A. Hormone replacement therapy in Leber's hereditary optic neuropathy: accelerated visual recovery *in vivo*. *J Curr Ophthalmol*, 2018, 31(1):102–105. <https://doi.org/10.1016/j.joco.2018.10.003> PMID: 30899856 PMCID: PMC6407313
- [15] Klopstock T, Yu-Wai-Man P, Dimitriadis K, Rouleau J, Heck S, Bailie M, Atawan A, Chattopadhyay S, Schubert M, Garip A, Kernt M, Petraki D, Rummey C, Leinonen M, Metz G, Griffiths PG, Meier T, Chinnery PF. A randomized placebo-controlled trial of Idebenone in Leber's hereditary optic neuropathy. *Brain*, 2011, 134(Pt 9):2677–2686. <https://doi.org/10.1093/brain/awr170> PMID: 21788663 PMCID: PMC3170530
- [16] Catarino CB, von Livonius B, Priglinger C, Banik R, Matloob S, Tamhankar MA, Castillo L, Friedburg C, Halfpenny CA, Lincoln JA, Traber GL, Acaroglu G, Black GCM, Doncel C, Fraser CL, Jakubaszko J, Landau K, Langenegger SJ, Muñoz-Negrete FJ, Newman NJ, Poulton J, Scoppettuolo E, Subramanian P, Toosy AT, Vidal M, Vincent AL, Votruba M, Zarowski M, Zermansky A, Lob F, Rudolph G, Mikazans O, Silva M, Llòria X, Metz G, Klopstock T. Real-world clinical experience with Idebenone in the treatment of Leber hereditary optic neuropathy. *J Neuroophthalmol*, 2020, 40(4):558–565. <https://doi.org/10.1097/WNO.0000000000001023> PMID: 32991388 PMCID: PMC7657145
- [17] Manickam AH, Michael MJ, Ramasamy S. Mitochondrial genetics and therapeutic overview of Leber's hereditary optic neuropathy. *Indian J Ophthalmol*, 2017, 65(11):1087–1092. https://doi.org/10.4103/ijo.IJO_358_17 PMID: 29133631 PMCID: PMC5700573
- [18] Tonagel F, Wilhelm H, Richter P, Kelbsch C. Leber's hereditary optic neuropathy: course of disease in consideration of Idebenone treatment and type of mutation. *Graefes Arch Clin Exp Ophthalmol*, 2021, 259(4):1009–1013. <https://doi.org/10.1007/s00417-020-05045-4> PMID: 33337510 PMCID: PMC8016777
- [19] Hage R, Vignal-Clermont C. Leber hereditary optic neuropathy: review of treatment and management. *Front Neurol*, 2021, 12:651639. <https://doi.org/10.3389/fneur.2021.651639> PMID: 34122299 PMCID: PMC8187781
- [20] Grochowski C, Symms M, Jonak K, Krukow P, Wood T, Ljungberg E, Enseñat J, Nowomiejska K, Rejdak R, Maciejewski R, Barker GJ. The evaluation of optic nerves using 7 Tesla "silent" zero echo time imaging in patients with Leber's hereditary optic neuropathy with or without Idebenone treatment. *J Clin Med*, 2020, 9(4):1112. <https://doi.org/10.3390/jcm9041112> PMID: 32295018 PMCID: PMC7230870

Corresponding author

Cornelia Andreea Tănăsie, Teaching Assistant, MD, PhD, Department of Physiology, University of Medicine and Pharmacy of Craiova, 2 Petru Rareș Street, 200349 Craiova, Dolj County, Romania; Phone +40766–212 416, e-mail: corici.andreea@gmail.com

Received: May 3, 2022

Accepted: August 20, 2022