



Frequency of *RPE65* Gene Mutation in Patients with Hereditary Retinal Dystrophy

© Neslihan Sinim Kahraman*, © Ayşe Öner*, © Yusuf Özkul**, © Munis Dünder**

*Acıbadem Kayseri Hospital, Clinic of Ophthalmology, Kayseri, Turkey

**Erciyes University Faculty of Medicine, Department of Medical Genetics, Kayseri, Turkey

Abstract

Objectives: Hereditary retinal dystrophies are a rare group of diseases which are heterogeneous in genotype and phenotype and result in total blindness. One of the genetic defects that cause hereditary retinal dystrophy is mutation of the *RPE65* gene. Genetic therapy studies in hereditary retinal dystrophies have increased in number recently, and important developments have been reported in these studies. Voretigene neparvovec-rzyl (Luxturna, Spark Therapeutics), a gene therapy drug for retinal dystrophy associated with *RPE65* mutation, received Food and Drug Administration approval in 2017. This study aimed to investigate the frequency and clinical findings of patients with *RPE65* gene defects, which may be amenable to genetic treatment.

Materials and Methods: The data of patients diagnosed with hereditary retinal dystrophy who were followed up between 2017 and 2021 were retrospectively reviewed. Of these, 460 patients with genetic analysis results were included in the study. The clinical findings of patients with homozygous (biallelic) *RPE65* mutation were screened.

Results: *RPE65* homozygous gene mutation was detected in only 11 of 460 cases (2.39%). Genetic results of the cases were presented in detail. The inheritance patterns of the cases were autosomal recessive. The demographic data and clinical findings were defined.

Conclusion: *RPE65* gene mutation is a very rare disorder. Genetic screening has gained importance with the emergence of gene therapy alternatives. New treatment methods are promising in cases for which there was no chance of a cure to date.

Keywords: *RPE65* gene, hereditary retinal dystrophy, gene therapy

Address for Correspondence: Neslihan Sinim Kahraman, Acıbadem Kayseri Hospital, Clinic of Ophthalmology, Kayseri, Turkey

E-mail: neslihansinim@gmail.com **ORCID-ID:** orcid.org/0000-0002-1409-1404

Received: 04.06.2021 **Accepted:** 01.10.2021

Cite this article as: Sinim Kahraman N, Öner A, Özkul Y, Dünder M. Frequency of *RPE65* Gene Mutation in Patients with Hereditary Retinal Dystrophy. Turk J Ophthalmol 2022;52:270-275

©Copyright 2022 by Turkish Ophthalmological Association
Turkish Journal of Ophthalmology, published by Galenos Publishing House.

Introduction

Hereditary retinal dystrophies are a rare and phenotypically heterogeneous group of diseases that can result in blindness. To date, nearly 250 genetic mutations have been identified, and studies continue to add new mutations to the literature. The disease exhibits a broad clinical spectrum. Clinical entities often cannot be clearly delineated and have overlapping findings.^{1,2,3}

Mutations in the *RPE65* gene are among the genetic defects that cause hereditary retinal dystrophy. Clinically, this mutation can be seen in cases of Leber congenital amaurosis (LCA2), severe early childhood-onset retinal dystrophy (SECORD), and non-syndromic retinitis pigmentosa (RP20).^{2,4,5} SECORD and LCA caused by genetic defects have similar features. Basically, LCA can be diagnosed if clinical findings occur within the first few months of life.^{1,2,3} The features of infancy-onset LCA include progressive visual impairment, nyctalopia, nystagmus, poor pupillary reaction, photophobia, and attenuated electroretinography (ERG) responses. The disease is progressive and can result in blindness in the third and fourth decades. SECORD is clinically milder, with onset between 4 and 6 years of age.^{6,7,8}

The *RPE65* gene is involved in vitamin A metabolism in the retinal pigment epithelium cells. Mutations in this gene are fairly rare, with an estimated prevalence of 1/50,000-100,000, and vary between populations.^{9,10,11}

Genetic therapy studies in hereditary retinal dystrophies have increased in number recently, and important developments have been reported in these studies. Voretigene neparvovec-rzyl (Luxturna, Spark Therapeutics) is a gene therapy drug for retinal dystrophy associated with *RPE65* mutation that received Food and Drug Administration (FDA) approval in 2017. Luxturna, the first product approved for hereditary retinal disease in the United States, was also approved for clinical use and introduced in 28 European Union member countries in November 2018.^{12,13}

The introduction of gene therapy has further increased the importance of conducting genetic analysis. The genetic and clinical heterogeneity of the disease leads to challenges in the diagnosis. Therefore, gene analysis is also important in terms of identifying the underlying genetic disorder, understanding the genotype-phenotype relationship, and confirming the diagnosis. Thus, patients can be provided counseling regarding future genetic therapy alternatives.

Another benefit of genetic analysis is that it enables genetic counseling of the family. Identifying the causative gene and knowing the inheritance pattern is also important in terms of prevention in our country, which has a high rate of consanguineous marriage. Genetic analysis enables carrier identification, pre-pregnancy counseling, prenatal diagnosis, definitive diagnosis of disease, and clinical prognosis.¹⁴

This study examined the results of patients who were diagnosed with hereditary retinal dystrophy and underwent genetic analysis in our clinic. The genetic and clinical characteristics of patients with *RPE65* gene mutation were investigated to identify patients eligible for genetic therapy.

Materials and Methods

Patient Identification and Evaluation

In this study, we retrospectively reviewed the records of patients with hereditary retinal dystrophy followed up in our clinic between 2017 and 2021. Ethics committee approval was obtained for the study (2021-09/14). A total of 460 patients with genetic analysis results were included in the study. Clinical examination findings of the patients were examined and best corrected visual acuity (BCVA) was measured with Snellen chart at a distance of 3 meters and recorded by converting to decimal and logMAR. Detailed fundus examination, visual field with Humphrey 30-2 program (Carl Zeiss Meditec AG, Germany), central macular thickness with optic coherence tomography (OCT), and full-field flash ERG (Metrovision, France) results were evaluated.

Genetic Tests

The patients' genetic analyses were performed in universities, training and research hospitals, and private genetic diagnosis centers. We contacted the geneticists in the relevant centers to obtain permission to use the data. Sixty patients were screened by whole exome sequencing (WES), 17 by clinical exome sequencing (CES), and 333 by retinitis pigmentosa (RP) panel for hereditary retinal disease, which includes the *RPE65* gene. Other than these, isolated *RPE65* gene screening was performed in 50 patients. Genetic analyses were performed with next-generation sequencing (NGS) technology using DNA isolated from peripheral blood samples.

Results

The study included 460 patients who were followed up in our clinic and had genetic analysis records. We examined the clinical findings of patients with homozygous (biallelic) *RPE65* mutations detected by genetic screening. Patients with mutations in other genes in addition to *RPE65* and patients with heterozygous *RPE65* mutations were excluded from the study.

Of the 460 cases screened, only 11 had homozygous *RPE65* gene mutations (2.39%). Of these, 5 patients were female and 6 were male. The patients underwent detailed ophthalmological examinations and their BCVA, fundus examination, visual field, OCT, and ERG findings were evaluated.

The inheritance pattern in these patients was autosomal recessive. In the results of genetic analysis, *RPE65* gene mutation variants were reported as pathogenic, likely pathogenic, or variants of unknown clinical significance; benign conditions were not included in the report. The report details of each patient are shown in Table 1. In the conclusion section of patients 2, 3, 4, and 11, it was reported that pathogenic and likely pathogenic mutations related to the *RPE65* gene could also lead to autosomal recessive LCA2 and RP20, as well as autosomal dominant RP with choroidal involvement. The report of patient 7 indicated that the relevant mutation causes RP20. In the patients' fundus examinations, early-stage patients showed pigment changes in the peripheral retina and areas of geographic atrophy, while

advanced patients showed optic disc pallor, narrowed vessels, and extensive peripheral bone spicules. Figure 1 shows the fundus photographs, OCT macular images, and visual field results of patient 5. All patients exhibited diffuse atrophy in the peripheral

retina, although the outer segment/inner segment junction in the subfoveal area was somewhat preserved in patients 1, 4, 5, 6, 7, 8, and 9. In the other patients, widespread disruption and atrophy of the outer segment was detected (Figure 2,3).

Table 1. Genetic analysis results of the patients

Patient No.	Test	Gene	Exon	Variant	Amino acid substitution	Zygoty	Pathogenicity	Inheritance
1	CES	<i>RPE65</i> NM_000329	?	c.858+1G>T	Unspecified	Homozygote	P	AR
2	RP Panel	<i>RPE65</i> NM_000329	5	c.433G>C	p.Ala145Pro	Homozygote	KÖB	AR
3	RP Panel	<i>RPE65</i> NM_000329	3	c.138del	p.Pro47Glnfs*47	Homozygote	P	AR
4	RP Panel	<i>RPE65</i> NM_000329	3	c.138del	p.Pro47Glnfs*47	Homozygote	P	AR
5	RP Panel	<i>RPE65</i> NM_000329	6	c.499G>T	P.Asp167Tyr	Homozygote	MP	AR
6	RP Panel	<i>RPE65</i> NM_000329	2	c.34delT	p.Tyr12Thrfs*19	Homozygote	MP	AR
7	RP Panel	<i>RPE65</i> NM_000329.2	9	c.908-999_169del	Unspecified	Homozygote	MP	AR
8	RP Panel	<i>RPE65</i> NM_000329.2	10	c.1039C>T	p.Arg347Cys	Homozygote	P	AR
9	RP Panel	<i>RPE65</i> NM_000329.2	10	c.1039C>T	p.Arg347Cys	Homozygote	P	AR
10	RP Panel	<i>RPE65</i> NM_000329.2	10	c.1039C>T	p.Arg347Cys	Homozygote	P	AR
11	RP Panel	<i>RPE65</i> NM_000329	14	c.1460T>C	p.Leu487Pro	Homozygote	MP	AR

KES: Klinik ekzom sekanslama, RP: Retinitis pigmentosa, P: Patojenik, MP: Muhtemel patojenik, KÖB: Klinik önemi bilinmeyen, OR: Orozomal resesif

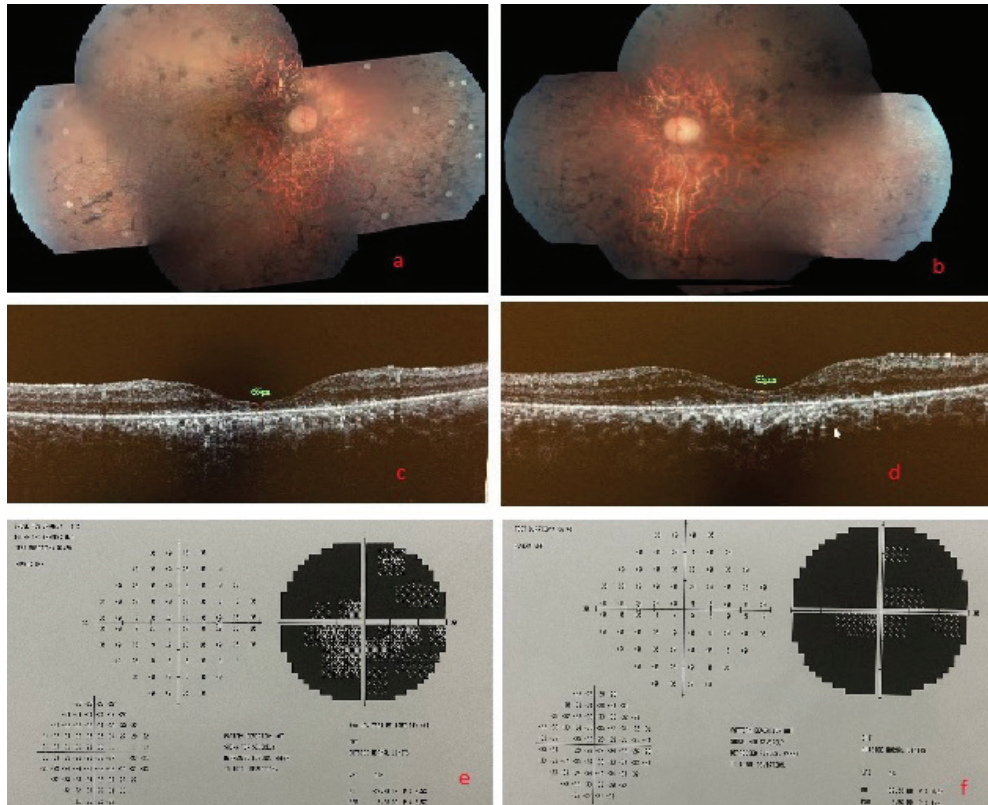


Figure 1. In patient 5, peripheral bone spicules, optic disc pallor, widespread retinal atrophy, and vessel narrowing were observed in right and left fundus photographs (a and b). Macular thinning on optical coherence tomography (c and d) and visual field narrowing (e and f) were also apparent

The age, age at diagnosis, BCVA, visual field mean deviation, and OCT central macular thickness of patients with homozygous *RPE65* mutation are shown in Table 2. These findings were accompanied by nystagmus in patients 1, 8, 9, 10, and 11. In addition, greater than 2 diopters of hyperopia and astigmatism were present in 4 patients and myopic astigmatism in 3 patients. In the other 4 patients, refractive errors were less than 2 diopters.

The patients' full-field flash ERG findings showed diminished responses in most patients. Patients 8, 9, and 10 were siblings. The other patients were unrelated cases.

Discussion

The *RPE65* (retinal pigment epithelium-specific 65 kDa protein) gene is expressed in the retinal pigment epithelium and is involved in vitamin A metabolism. It encodes the enzyme responsible for the isomerization of all-trans-retinyl esters to 11-cis retinol. Mutation in this gene leads to retinyl ester accumulation in the retinal pigment epithelial cells. The visual cycle is disrupted and electrical signals cannot be generated.

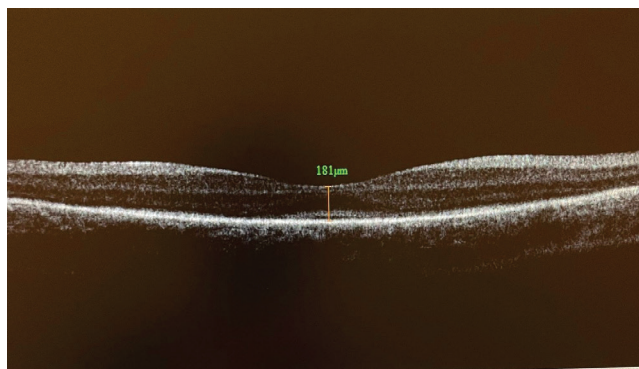


Figure 2. In patient 1, optical coherence tomography demonstrated some preservation of central macular thickness and the retinal outer segment/inner segment junction

Degeneration of the retinal pigment epithelium and neural retina results in vision loss.^{5,15}

The frequency of *RPE65* gene mutation varies between populations. RP20, one of the clinical manifestations of *RPE65* gene mutation, accounts for 1-2% of autosomal recessive RP cases.⁵ Studies screening patients with LCA associated with *RPE65* mutation reported prevalence rates between 1% and 16% depending on the geographic region.^{11,16,17,18,19} In our study, we screened the genetic results of all patients with hereditary retinal dystrophy, not only LCA, and found homozygous *RPE65* gene mutation in 11 (2.39%) of 460 patients.

From previous studies and the new mutations added to the literature, 138 different mutations in the *RPE65* gene have been identified to date.²⁰ The phenotypic reflection of *RPE65* gene mutations may vary between patients.²¹ Six of our patients (including 3 siblings) were found to be consistent with a diagnosis of LCA because of clinical onset in infancy, the presence of nystagmus and weak pupillary reaction, and diminished ERG responses. The other 5 patients were diagnosed after the age of

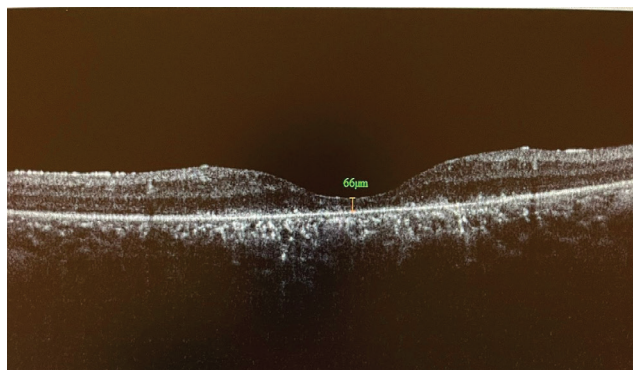


Figure 3. In patient 5, optical coherence tomography showed an extensive retinal degeneration with severe central macular thinning and complete disruption of the retinal outer segment/inner segment junction

Table 2. Clinical findings of our patients

Patient no.	Sex	Age	Age at diagnosis	VA (decimal) right/left	VA (logMAR) right/left	VF MD Value right/left	OCT CMT (μm) right/left
1	F	25 y	5 y	0.05/0.05	1.3/1.3	32.95/32.75	181/170
2	F	33 y	11 y	1 m HM/1 m HM	2.3/2.3	33.52/33.56	160/185
3	M	26 y	4 mo	P/P	2.5/2.5	33.83/33.81	165/155
4	F	15 y	5 mo	0.05/0.05	1.3/1.3	27.89/28.21	194/214
5	M	29 y	7 y	0.3/0.05	0.5/1.3	29.99/32.50	66/83
6	F	12 y	6 y	2 m CF/2 m CF	2.3/2.3	31.13/29.79	160/148
7	M	11 y	6 mo	0.3/0.15	0.5/0.8	26.53/27.41	190/210
8	F	13 y	4 mo	0.05/0.05	1.3/1.3	30.41/30.98	111/120
9	M	11 y	3 mo	2 m CF/2 m CF	2.3/2.3	34.68/34.42	84/80
10	M	3 y	3 mo	0.1/0.1	1/1	-	95/90
11	M	46 y	7 y	LP/LP	2.5/2.5	32.82/32.82	74/79

M: Male, F: Female, y: Years, mo: Months, VA: Visual acuity, m: Meter, CF: Counting fingers, HM: Hand movements, LP: Light perception, VF: Visual field, MD: Mean deviation, OCT: Optical coherence tomography, CMT: Central macular thickness, -: The patient could not cooperate with the test.

5 years. These patients' diagnosis could be SECORD or RP20. A study on SECORD and LCA indicated that the RPE65 gene was more associated with SECORD.⁸ A diagnosis of SECORD is more likely in our other 5 patients.

It is known that the underlying genetic defect provides insight into the clinical manifestation and disease course that will occur. However, clinical variation between patients and even between family members with the same defect has been reported.⁸ Although all of the patients in this study had *RPE65* gene mutations, their age at onset and clinical courses differed. Patients 3 and 4, who were consistent with LCA, had the same mutation (c.138del) and similar clinical features. In addition, sibling patients 8, 9, and 10 (c.1039C>T) had the same clinical findings, with onset in infancy and rapid progression.

Natural history studies have indicated that the disease course is heterogeneous, and the age at onset, clinical findings, and disease severity vary between patients. It was reported that vision level significantly decreases in the first decade, and deterioration of visual acuity and visual field progresses in the second and third decades. Although visual impairment and visual field loss with age are certain, it was emphasized that there may be individual differences. The same patient may exhibit slow progression over the years, as well as exhibit rapid clinical deterioration after a period of stability.^{22,23}

All of our patients exhibited significant loss of vision in the first decade. When the clinical findings are examined, 19 of 22 eyes had BCVA below 20/400 (0.05 decimal, 1.3 logMAR). These patients, who also have loss in the central 10 degrees of the visual field, are legally blind according to the World Health Organization ICD-10 coding.²⁴ In a similar study in the literature, vision loss was reported to progress gradually starting in the first decade and reaching the level of legal blindness (logMAR 1.0, Snellen 20/200) in the second decade.²⁵

Studies on gene therapy have accelerated in recent years, and Luxturna completed randomized controlled phase 3 trials and received FDA approval. The phase 3 trial demonstrated the efficacy and safety of the drug, with patients exhibiting increased light sensitivity and improved visual field and performance on mobility tests performed in different lighting.²⁶

Patients eligible for gene therapy were identified as those aged 3 years and older with a biallelic (homozygous) *RPE65* gene mutation, visual acuity of 20/60 (0.33 decimal) or less, and more than 20 degrees of visual field narrowing. In order for gene therapy to exert its effect and correct retinal pigment epithelium function, it is essential that there are viable cells in the retina. In advanced cases, extensive degeneration of the outer retinal layers reduces the effectiveness of treatment. To address this, it was reported that the patient must have greater than 100 µm retinal thickness and a level of vision sufficient to perform mobility tests conducted under different lighting conditions. It is recommended that retinal degeneration should not be advanced and treatment should be administered in the early stage. Although the drug prospectus states it can be used

in patients over 1 year of age, the consensus is that accepting patients over 3 of age would be more appropriate in terms of vitrectomy-related complications.^{12,13,26,27,28}

While all the patients in our study were over the age of 3 years, patients 2, 3, and 11 did not have sufficient visual acuity for the mobility test, and macular thickness was less than 100 µm in patients 5, 9, 10, and 11. Therefore, these patients are not eligible for gene therapy according to the criteria defined. The remaining 5 patients meet the treatment criteria.

Study Limitations

As the disease process is chronic and progressive, longer follow-up would provide more detailed information about disease progression. However, clinical course may not be predictable due to the heterogeneity of the disease and the individual differences in clinical course. In addition, because of the small case number, we could not establish a correlation between the mutations detected and clinical presentation. These data may be obtained in larger-scale studies with longer follow-up.

Conclusion

RPE65 gene mutation is a very rare disorder that can lead to the clinical manifestations of LCA2 and RP20. With the introduction of gene therapy alternatives, genetic screening has gained importance. New treatment methods are promising for patients for whom a cure was not previously possible. Genetic analysis provides guidance in patients' clinical diagnosis, prognosis, and genotype association and is also important in terms of emerging gene therapies.

Acknowledgements: We would like to thank Prof. Dr. Munis Dünder and Dr. Muhammed Ensar Doğan of Erciyes University Faculty of Medicine, Department of Genetics, who contributed with the results of genetic analysis, and our colleagues from the other departments, Dr. Bülent Uyanık, Dr. Nefise Kandemir, Dr. Özlem Akgün Doğan, Dr. Hakan Bağış Erdem, and Assoc. Prof. Dr. Serdar Ceylaner for their valuable contributions.

Ethics

Ethics Committee Approval: Acıbadem Mehmet Ali Aydınlar University Medical Research Evaluation Board (ATADEK) 2021-09/14.

Peer-review: Externally peer reviewed.

Authorship Contributions

Concept: A.Ö., Design: A.Ö., Data Collection or Processing: A.Ö., N.S.K., Y.Ö., M.D., Analysis or Interpretation: A.Ö., N.S.K., Y.Ö., M.D., Literature Search: A.Ö., N.S.K., Writing: A.Ö., N.S.K.

Conflict of Interest: No conflict of interest was declared by the authors.

Financial Disclosure: The authors declared that this study received no financial support.

References

- Lorenz B, Gyürüs P, Preising M, Bremser D, Gu S, Andrassi M, Gerth C, Gal A. Early-onset severe rodcone dystrophy in young children with RPE65 mutations. *Invest Ophthalmol Vis Sci.* 2000;41:2735-2742.
- Kumaran N, Moore AT, Weleber RG, Michaelides M. Leber congenital amaurosis/early-onset severe retinal dystrophy: clinical features, molecular genetics and therapeutic interventions. *Br J Ophthalmol.* 2017;101:1147-1154.
- Lorenz B, Poliakov E, Schambeck M, Friedburg C, Preising MN, Redmond TM. A comprehensive clinical and biochemical functional study of a novel RPE65 hypomorphic mutation. *Invest Ophthalmol Vis Sci.* 2008;49:5235-5242.
- Sevik MO, Şahin Ö. Leber Konjenital Amorozi. *Güncel Retina* 2021;5:173-184.
- Öner A. Recent Advancements in Gene Therapy for Hereditary Retinal Dystrophies. *Turk J Ophthalmol.* 2017;47:338-343.
- Allikmets R. Leber congenital amaurosis: a genetic paradigm. *Ophthalmic Genet.* 2004;25:67-79.
- Redmond TM, Poliakov E, Yu S, Tsai JY, Lu Z, Gentleman S. Mutation of key residues of RPE65 abolishes its enzymatic role as isomerohydrolase in the visual cycle. *Proc Natl Acad Sci U S A.* 2005;102:13658-13663.
- Koenekoop RK. An overview of Leber congenital amaurosis: a model to understand human retinal development. *Surv Ophthalmol.* 2004;49:379-398.
- den Hollander AI, Roepman R, Koenekoop RK, Cremers FP. Leber congenital amaurosis: genes, proteins and disease mechanisms. *Prog Retin Eye Res.* 2008;27:391-419.
- Stone EM. Leber congenital amaurosis - a model for efficient genetic testing of heterogeneous disorders: LXIV Edward Jackson memorial lecture. *Am J Ophthalmol.* 2007;144:791-811.
- Mamatha G, Srilekha S, Meenakshi S, Kumaramanickavel G. Screening of the RPE65 gene in the Asian Indian patients with leber congenital amaurosis. *Ophthalmic Genet.* 2008; 29:73-78.
- U.S. Food & Drug Administration. FDA approves novel gene therapy to treat patients with a rare form of inherited vision loss. Available at: <https://www.fda.gov/news-events/press-announcements/fda-approves-novel-gene-therapy-treat-patients-rare-form-inherited-vision-loss>. Accessed 10 June 2020.
- European Medicines Agency. Luxturna Authorisation Details. Available at: <https://www.ema.europa.eu/en/medicines/human/EPAR/luxturna>. Accessed 10 June 2020.
- LUXTURNA (voretigene neparvec-rzyl) US Full Prescribing Information. 2017; Available from: http://sparktx.com/LUXTURNA_US_Prescribing_Information.pdf.
- Cai X, Conley SM, Naash MI. RPE65: role in the visual cycle, human retinal disease, and gene therapy. *Ophthalmic Genet.* 2009;30:57-62.
- Verma A, Perumalsamy V, Shetty S, Kulm M, Sundaresan P. Mutational screening of LCA genes emphasizing RPE65 in South Indian cohort of patients. *PLoS One.* 2013;8:e73172.
- Li Y, Wang H, Peng J, Gibbs RA, Lewis RA, Lupski JR, Mardon G, Chen R. Mutation survey of known LCA genes and loci in the Saudi Arabian population. *Invest Ophthalmol Vis Sci.* 2009;50:1336-1343.
- Xu F, Dong Q, Liu L, Li H, Liang X, Jiang R, Sui R, Dong F. Novel RPE65 mutations associated with Leber congenital amaurosis in Chinese patients. *Mol Vis.* 2012;18:744-750.
- Simonelli F, Ziviello C, Testa F, Rossi S, Fazzi E, Bianchi PE, Fossarello M, Signorini S, Bertone C, Galantuomo S, Brancati F, Valente EM, Ciccodicola A, Rinaldi E, Auricchio A, Banfi S. Clinical and molecular genetics of Leber's congenital amaurosis: a multicenter study of Italian patients. *Invest Ophthalmol Vis Sci.* 2007;48:4284-4290.
- Stenson PD, Mort M, Ball EV, Evans K, Hayden M, Heywood S, Hussain M, Phillips AD, Cooper DN. The human gene mutation database: towards a comprehensive repository of inherited mutation data for medical research, genetic diagnosis and next-generation sequencing studies. *Hum Genet.* 2017;136:665-677.
- Weleber RG, Michaelides M, Trzuppek KM, Stover NB, Stone EM. The phenotype of severe early childhood onset retinal dystrophy (SECORD) from mutation of RPE65 and differentiation from leber congenital amaurosis. *Invest Ophthalmol Vis Sci.* 2011;52:292-302.
- Chung DC, Bertelsen M, Lorenz B, Pennesi ME, Leroy BP, Hamel CP, Pierce E, Sallum J, Larsen M, Stieger K, Preising M, Weleber R, Yang P, Place E, Liu E, Schaefer G, DiStefano-Pappas J, Elci OU, McCague S, Wellman JA, High KA, Reape KZ. The Natural History of Inherited Retinal Dystrophy Due to Biallelic Mutations in the RPE65 Gene. *Am J Ophthalmol.* 2019;199:58-70.
- Paunescu K, Wabbels B, Preising MN, Lorenz B. Longitudinal and cross-sectional study of patients with early-onset severe retinal dystrophy associated with RPE65 mutations. *Graefes Arch Clin Exp Ophthalmol.* 2005;243:417-426.
- WHO. International statistical classification of diseases and related health problems 10th revision. Geneva; Protection of the human environment occupational and environmental health series. 1999.
- Ciulla TA, Hussain RM, Berrocal AM, Nagiel A. Voretigene Neparvec-rzyl for Treatment of RPE65-Mediated Inherited Retinal Diseases: A Model for Ocular Gene Therapy Development. *Expert Opin Biol Ther.* 2020;20:565-578.
- Russell S, Bennett J, Wellman JA, Chung DC, Yu ZF, Tillman A, Wittes J, Pappas J, Elci O, McCague S, Cross D, Marshall KA, Walshire J, Kehoe TL, Reichert H, Davis M, Raffini L, George LA, Hudson FP, Dingfield L, Zhu X, Haller JA, Sohn EH, Mahajan VB, Pfeifer W, Weckmann M, Johnson C, Gewaily D, Drack A, Stone E, Wachtel K, Simonelli F, Leroy BP, Wright JF, High KA, Maguire AM. Efficacy and safety of voretigene neparvec (AAV2-hRPE65v2) in patients with RPE65-mediated inherited retinal dystrophy: a randomised, controlled, open-label, phase 3 trial. *Lancet.* 2017;390:849-860.
- Sengillo JD, Justus S, Tsai YT, Cabral T, Tsang SH. Gene and cell-based therapies for inherited retinal disorders: An update. *Am J Med Genet C Semin Med Genet.* 2016;172:349-366.
- Cideciyan AV, Jacobson SG, Beltran WA, Sumaroka A, Swider M, Iwabe S, Roman AJ, Olivares MB, Schwartz SB, Komáromy AM, Hauswirth WW, Aguirre GD. Human retinal gene therapy for Leber congenital amaurosis shows advancing retinal degeneration despite enduring visual improvement. *Proc Natl Acad Sci USA.* 2013;110:517-525.