



# A Retinitis Pigmentosa Sine Pigmento Case with Bilateral Optic Disc Druzen and Cystoid Macular Edema

Esra Bahadır Camgoz<sup>1</sup> , Berrak Sekeryapan Gediz<sup>1</sup> 

## ABSTRACT

Retinitis pigmentosa sine pigmento (RPSP) is an atypical form of retinitis pigmentosa without hyper-pigmented lesions in the fundus. Diagnosis is difficult due to the absence of typical fundus findings. In this report, we present a case of RPSP associated with optic disc drusen and cystoid macular edema in which best corrected visual acuity was 0.5 in the right eye and 0.7 in the left. The aim of this report is to demonstrate a case of RPSP who presented with unexplained vision loss in both eyes and was diagnosed with multimodal imaging methods.

**Keywords:** Electroretinography, Carbonic anhydrase inhibitor, Cystoid macular edema, Optic disc drusen, Retinitis pigmentosa sine pigmento.

## INTRODUCTION

Retinitis Pigmentosa (RP), most common inherited disease of retina, is characterized by progressive loss of photoreceptors and retinal pigment epithelium (RPE) dysfunction. In most cases, degeneration primarily involves rods while cones are affected secondarily. Major symptoms are progressive loss of vision, night blindness and visual field defects. In RP, typical fundus finding is hyper-pigmented lesions, also termed as bone spicule, at peripheral retina. In addition, further findings have been reported, including cataract, epiretinal membrane, cystoid macular edema (CME) and optic disc drusen (ODD). The diagnosis is made by family history, clinical findings, electroretinography (ERG) and ocular imaging studies.<sup>1-2</sup>

In addition to its typical form, RP has many atypical form and can manifest with different clinical presentations. The atypical forms include retinitis pigmentosa sine pigmento (RPSP) which is characterized by lack of retinal pigment; sector RP involving a single segment of retina; pericentral RP where pigment alterations are present at pericentral region; unilateral RP which involves one eye; retinitis punctata albescence which manifests with diffuse, small white spots in retina; inverse (central) RP in which pigmentation is present at macular region and central vision is impaired while peripheral vision is preserved;

and RP with exudative vasculopathy where exudative retinal detachment is observed together with telangiectatic vascular anomaly and lipid accumulation at peripheral retina.<sup>3, 4, 5</sup> In addition, it may association with several syndromes such as Usher syndrome or Bardett-Biedl syndrome.<sup>2</sup>

Retinitis pigmentosa sine pigmento is one of the atypical forms of RP and diagnosis may be challenging due to absence of hyper-pigmented lesions at fundus.<sup>6</sup> However, ERG and imaging findings can aid diagnosis. Here, we present a RPSP case accompanied by bilateral ODD and CME who presented with unexplained loss of vision in both eyes and diagnosed using multimodal imaging studies.

## Case Report

A 14-years old girl presented to our clinic with impaired vision in both eyes which started a month ago. In her history, it was found out that eye glasses were prescribed for this complaint; however, no improvement was noted in her complaints. In the ophthalmological examination, best-corrected visual acuity, as measured by Snellen charts, was 0.5 in the right eye and 0.7 in the left eye. The intraocular pressure and anterior segment examination were found to be normal. In fundus examination, optic disc margins were slightly blurred in both eyes and macula swelling

1- University of Health Sciences, Ulucanlar Eye Training and Research Hospital, Ophthalmology Department, Ankara, Turkey

**Received:** 08.11.2020

**Accepted:** 18.12.2020

*Ret-Vit* 2022; 31: 172-176

DOI:10.37845/ret.vit.2022.31.29

**Correspondence Address:**

Esra Bahadır Camgoz

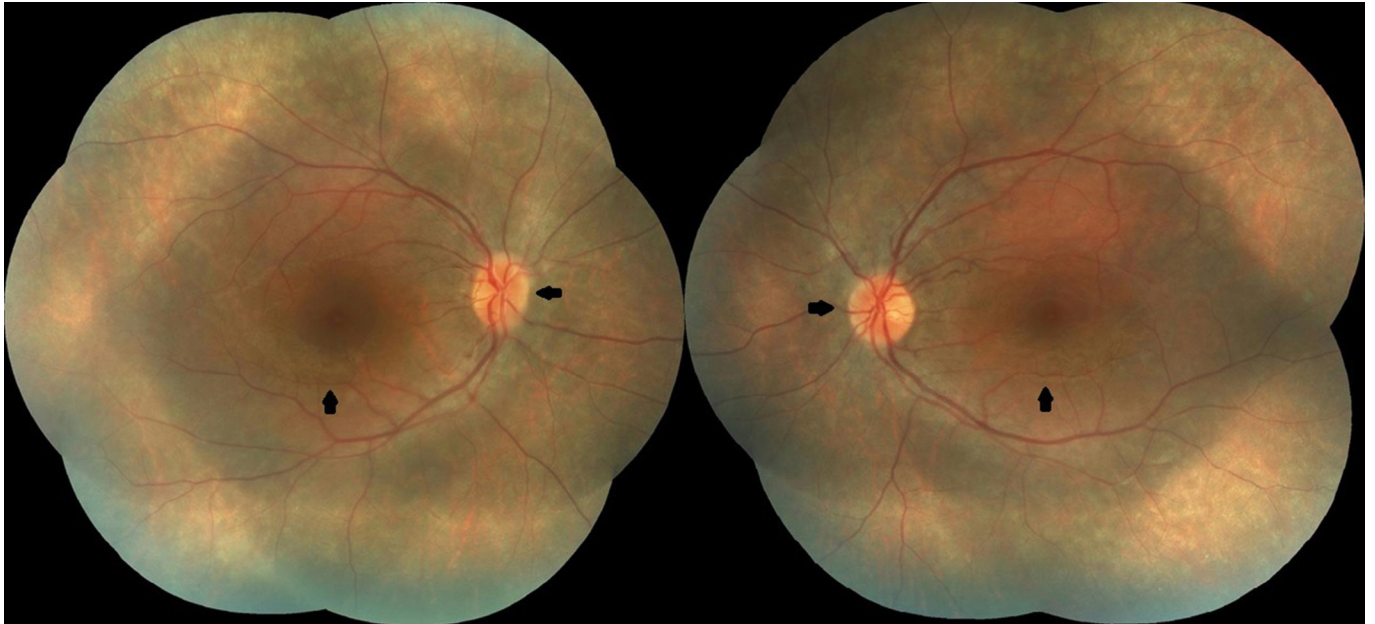
University of Health Sciences, Ulucanlar Eye Training and Research Hospital, Ophthalmology Department, Ankara, Turkey

**Phone:** -90 537 299 7467

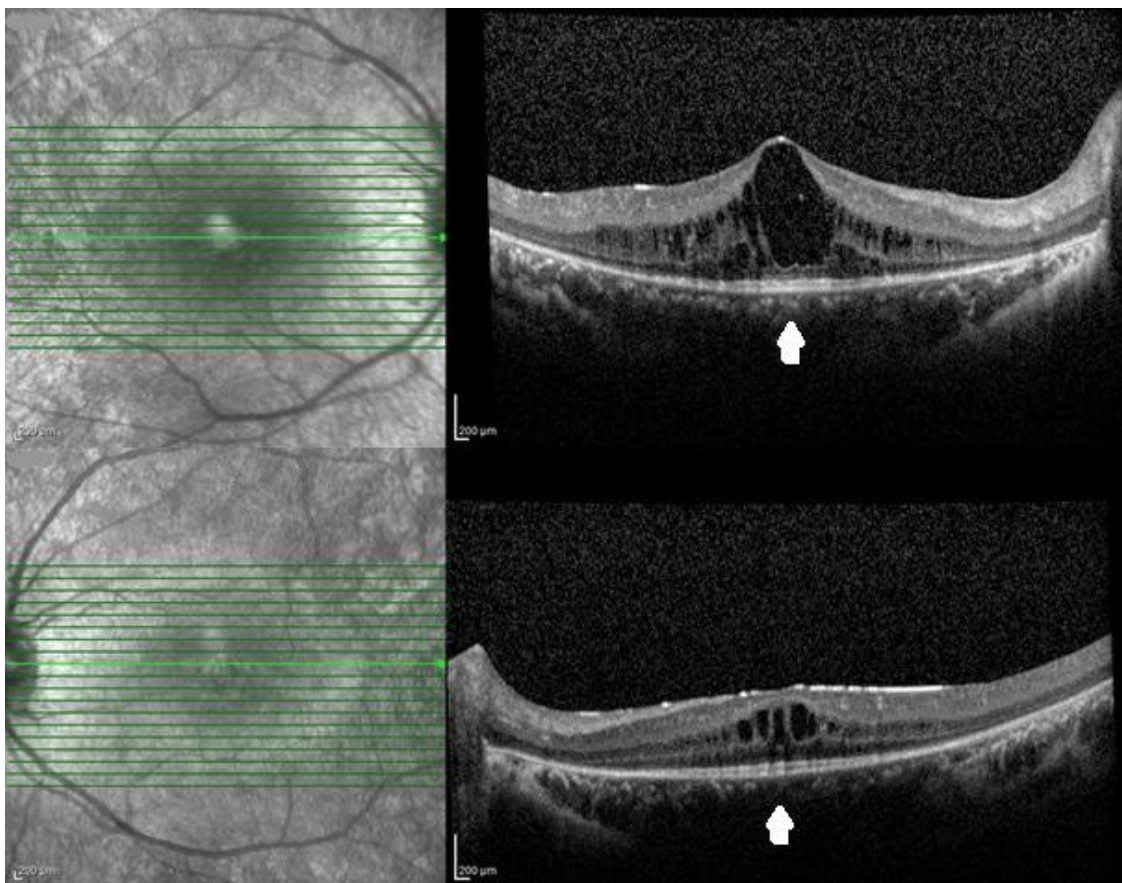
**E-mail:** esrabhdr@gmail.com

was observed (Figure 1) (Visucam 500 Fundus Camera, Zeiss, Germany). No additional pathology was noted in fundus examination. On OCT imaging (OCT Spectralis, Heidelberg Engineering, Germany), bilateral CME was

observed while no photoreceptor layer was detected other than a limited area at central region (Figure 2). On B-mode sonography (Compact Touch Ophthalmic Ultrasound - A/B Scans and Pachymetry, Quantel Medical, France), an



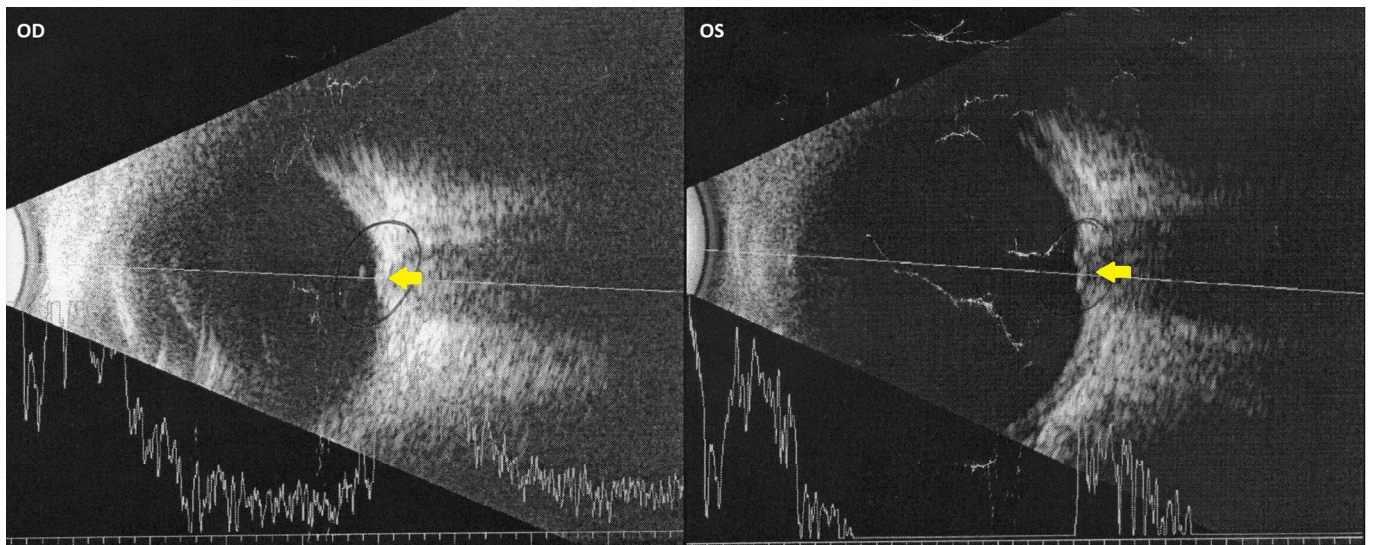
**Figure 1:** Blurred optic disc margins and macular swelling are seen in bilateral color fundus photographs (black arrows).



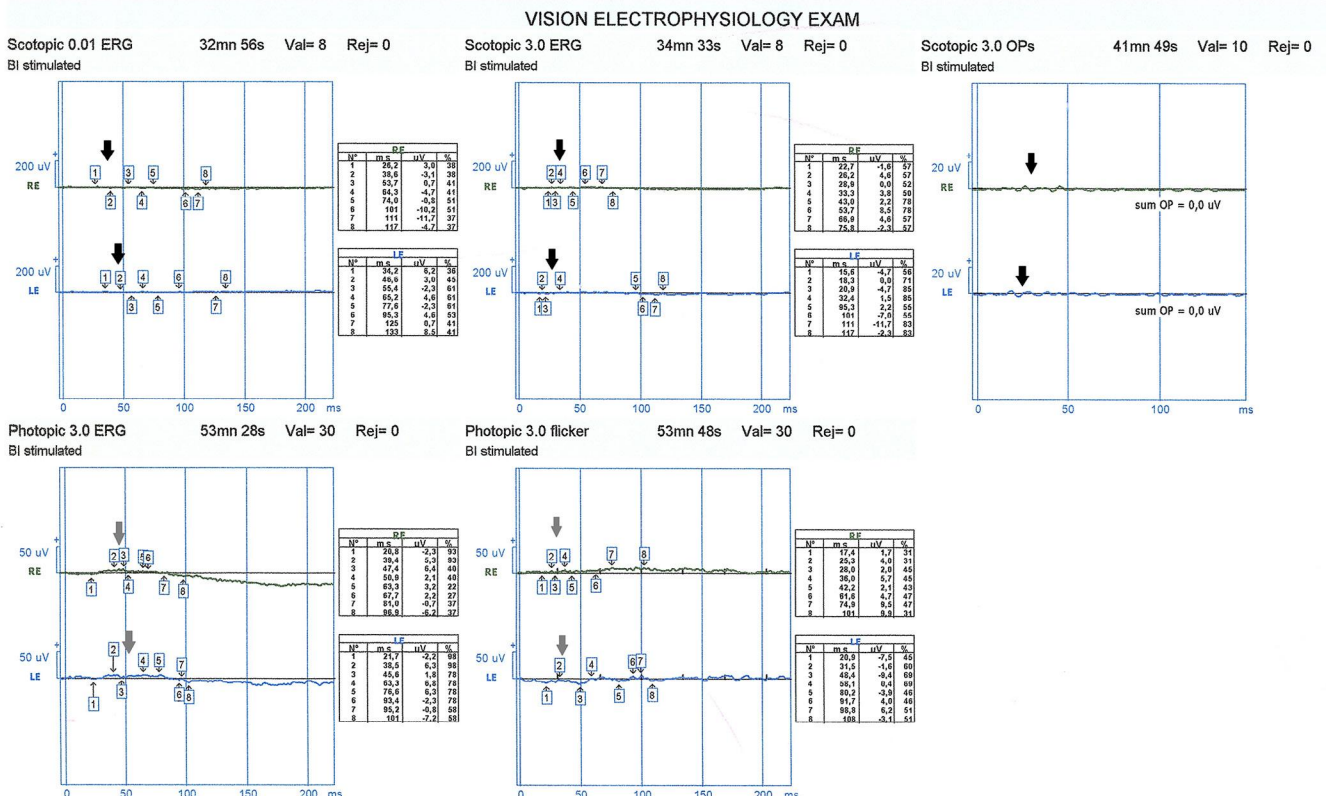
**Figure 2:** On OCT images, no photoreceptor layer can be observed in areas other than a limited central region (white arrows) and CME can be seen in both eyes.

image compatible with drusen was observed at optic nerve head in both eyes (Figure 3). On electroretinography (ERG) (MonPack One Visual Stimulator, Metrovision, France), it was found that there was reduction in rod response, and, in lesser extent, in cone response in both eyes, which was considered to be compatible with RP (Figure 4). The magnetic resonance imaging and neurological examination were normal; thus, the patient was diagnosed

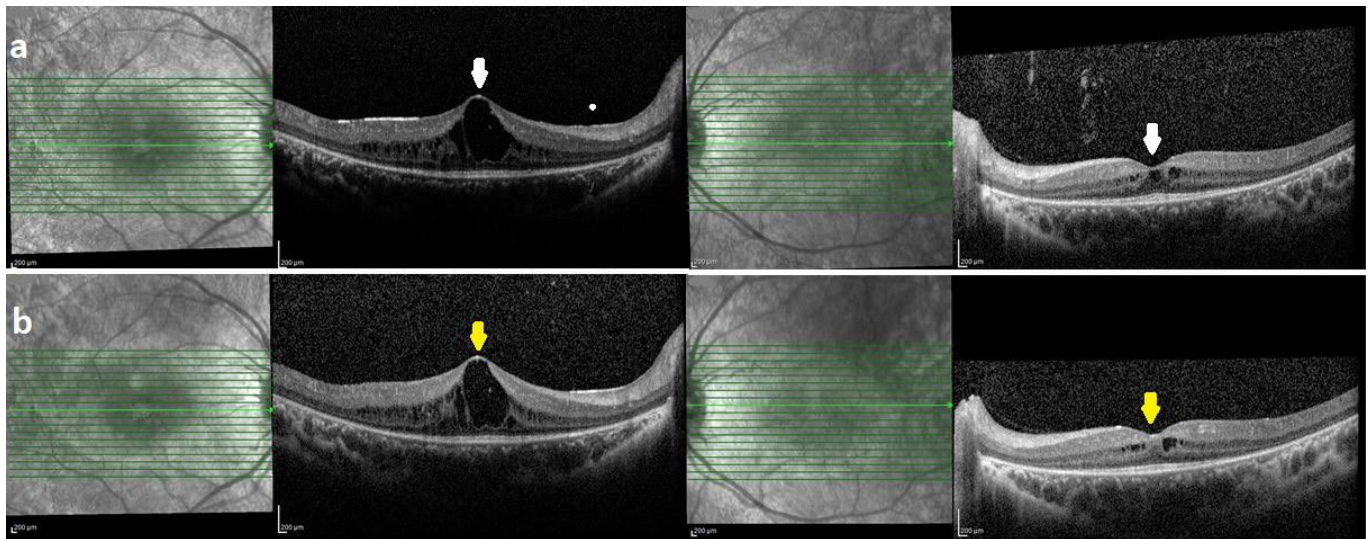
as RPSP accompanied by bilateral ODD and CME. Topical brinzolamide (twice daily) was given for CME. On the control visit at 1st month, no marked change was detected in CME in right eye while limited regression was noted in left eye (Figure 5a). At 6th month, BCVA was found as 0.5 and 0.9 in right and left eyes, respectively. OCT findings of the patient at the 6th month follow-up were similar to the 1st month findings. (Figure 5b).



**Figure 3:** On bilateral B-mod sonography, drusen is seen at optic nerve head in both eyes (yellow arrows).



**Figure 4:** On ERG testing, the decreased rod (black arrow) and cone response (gray arrow), as being at greater extent in rod response, are seen in both eyes.



**Figure 5:** **a)** On OCT images at 1st month, no marked change is seen in right eye but a slight regression is observed in CME in left eye (white arrow); **b)** the findings at 6th month are similar with those noted at 1st month (yellow arrows)

## DISCUSSION

Retinitis pigmentosa sine pigmento means non-pigmented RP and is a RP form where intraretinal pigmentation, typical finding of RP, is lacking. Particularly at early stages, absence of clinical findings such as blurred optic disc and thinning in retinal vascularity makes diagnosis challenging. The hyper-pigmentations, also termed as bone spicule, consist of melanin-containing cells clustered around vessels and it is thought that they develop due to migration of RPE to neurosensory retina in response to photoreceptor cell death.<sup>7</sup> Bone spicules may not be seen at early phases and in some forms of RP<sup>8</sup> It is unknown why RPE cells migrate to inner retina from Bruch's membrane after photoreceptor death. Cytokines released from vascular endothelium or high vascular flow may play role in RPE migration. The individual variations in such conditions may explain differences in amount and distribution of pigmentation among RP genotypes.<sup>8</sup>

In previous studies, it was shown that pigmentary changes developed in retina at long-term in some patients with RPSP.<sup>8</sup> In a study on RPSP patients, Takahashi et al. showed pigmentation in 10 of 27 patients during follow-up and mean time for pigmentation was found as 5.4 years based on Kaplan-Meier curve.<sup>9</sup> However, there are RPSP cases diagnosed at advanced age in the literature.<sup>6</sup> In our case, absence of fundus findings of RP may be due to younger age of patient and RP at first stage. However, occurrence of changes in pigmentation should be monitored at long-term follow-up in order to rule out RPSP.

Cystoid macular edema is a complication that may lead premature loss of vision in RP patients and its prevalence has been reported between 11% and 49%.<sup>10</sup> Oral or topical

carbonic anhydrase inhibitors have long been used in the treatment of CME. In a meta-analysis on effects of carbonic anhydrase inhibitors in CME developed in RP, Huang et al. reported that the treatment is associated with favorable anatomic outcomes but its effects on functional outcomes are variable.<sup>10</sup> In addition, in a study on efficacy of topical brinzolamide therapy on CME in patients with RP, it was shown that the topical brinzolamide therapy decreased central macular thickness but no improvement in visual acuity.<sup>11</sup> In our case, topical carbonic anhydrase inhibitor achieved favorable anatomic and functional outcomes in left eye but not right eye. Despite absence of typical fundus findings, the frequent association of RP with CME suggested RP in our case.

Optic disc drusen is non-cellular deposition at optic nerve head and is generally bilateral. Its prevalence is 0.3-2.4% in general population.<sup>12</sup> ODD prevalence varies widely in RP patients, ranging from 1.4% to 80%.<sup>13</sup> When compared to general population, higher prevalence of ODD in RP patients suggest higher predisposition to intraocular calcification.<sup>13</sup>

In conclusion, RPSP is a form of RP where no pigmentary changes observed in fundus examination and making diagnosis is challenging. Associated findings include optic disc drusen and CME. In these cases, ERG is highly important for diagnosis. Fundus autofluorescence imaging is also important in the diagnosis of RP. However, we failed to obtain autofluorescence imaging in our case. OCT and B-mode sonography may be helpful in diagnosis. Topical carbonic anhydrase inhibitors can be used in the treatment of CME.

**REFERENCES**

1. Hartong DT, Berson EL, Dryja TP. Retinitis pigmentosa. *Lancet*. 2006;368:1795-809.
2. Hamel C. Retinitis pigmentosa. *Orphanet J Rare Dis*. 2006;1:40.
3. O'dwyer PA, Akova YA. Temel Göz Hastalıkları. In: Akar S, Akyol S: *Retina Embriyogenezi-Fizyolojisi, Muayene Yöntemleri, Retina Dejeneresansları, Güneş Tıp Kitabevleri*. Ankara 2015;646.
4. Bhattarai D, Paudel N, Adhikari P, et al. Unilateral retinitis pigmentosa. *Nepal J Ophthalmol*. 2015;7:56-9.
5. Ferrucci S, Anderson SF, Townsend JC. Retinitis pigmentosa inversa. *Optom Vis Sci*. 1998;75:560-70.
6. Ma L, Sheng XL, Li HP, et al. Identification of a novel p.R1443W mutation in RP1 gene associated with retinitis pigmentosa sine pigmento. *Int J Ophthalmol*. 2013;6:430-5.
7. Li ZY, Possin DE, Milam AH. Histopathology of Bone Spicule Pigmentation in Retinitis Pigmentosa. *Ophthalmology*. 1995;102:805-16.
8. Berson EL, Rosner B, Simonoff E. Risk factors for genetic typing and detection in retinitis pigmentosa. *Am J Ophthalmol*. 1980;89:763-75.
9. Takahashi VKL, Takiuti JT, Jauregui R, et al. Rates of Bone Spicule Pigment Appearance in patients with Retinitis Pigmentosa Sine Pigmento, *American Journal of Ophthalmology*. 2018;195:176-80.
10. Huang Q, Chen R, Lin X, et al. Efficacy of carbonic anhydrase inhibitors in management of cystoid macular edema in retinitis pigmentosa: A meta-analysis. *PLoSOne*. 2017;12:e0186180.
11. Alkın Z, Özkaya A, Karataş G, et al. Retinitis Pigmentozaaya Bağlı Kistoid Maküla Ödeminde Topikal Brinzolamid Tedavisi. *Ret-Vit* 2013;21:82-6.
12. Hamann S, Malmqvist L, Costello F. Optic disc drusen: understanding an old problem from a new perspective. *Acta Ophthalmol*. 2018;96:673-84.
13. Novack RL, Foos RY. Drusen of the optic disk in retinitis pigmentosa. *Am J Ophthalmol*. 1987;103:44-7.