

## Relationship between optical coherence tomography angiography and visual evoked potential in patients with multiple sclerosis

Sedat Ava, Yusuf Tamam<sup>1</sup>, Leyla Hazar, Mine Karahan, Seyfettin Erdem, Mehmet Emin Dursun, Ugur Keklikçi

**Purpose:** This study aimed to identify an easy-to-apply biomarker by correlating visual evoked potential (VEP) with optical coherence tomography angiography (OCTA) results in multiple sclerosis (MS). **Methods:** Our study was planned prospectively. Patients with MS were divided into two groups, VEP prolonged group 1 and VEP normal group 2. Age-matched and gender-matched healthy individuals (group 3) were included as the control group. Vascular density (VD) of the optic nerve head (ONH) and radial peripapillary capillaries (RPCs) were measured and recorded by OCTA. The optic nerve damage of patients was measured and recorded with a VEP device. **Results:** Thirty-two eyes were included in group 1, 50 eyes were included in group 2, and 51 healthy eyes were included in group 3. In terms of visual acuity, group 1 was significantly lower than the other groups ( $P < 0.001$ ). Regardless of the prolongation of p100 latency in patients with MS, whole image, inside disc ONH VD and in the same sectors in RPC VD were found to be significantly lower than the control group ( $P < 0.05$ ). Retinal nerve fiber layer thickness was found to be significantly lower in group 1 than in group 2 and group 3 ( $P < 0.05$ ). There was a significant correlation between low ONH VD and RPC VD and prolonged VEP P100 ( $P < 0.05$ ). **Conclusion:** VEP measurements can be correlated with OCTA measurements in patients with MS and can be used as a biomarker to determine the degree of optic nerve damage.

**Key words:** Multiple sclerosis, optical coherence tomography angiography, visual evoked potential

Multiple sclerosis (MS) is a disease that typically occurs in young adults and results in central nervous system inflammation, demyelination, neuroaxonal loss, and widespread degeneration. Many factors, including inflammatory, autoimmune, genetic, and vascular factors, play a role in its etiology.<sup>[1,2]</sup> MS is thought to be an autoimmune disease that develops due to inflammation caused by the T cells acting against the myelin sheath in the central nervous system (CNS).<sup>[3]</sup> The age of onset is usually around 30 years old, and women are affected about two times more than men.<sup>[4]</sup>

Cerebral vascular changes due to vasculopathy in MS play an important role in the pathogenicity and prognosis of the disease.<sup>[5]</sup> Cerebral vessels and retinal vessels are embryologically similar, structurally and anatomically, because they originate from the same structure.<sup>[5]</sup> Therefore, it is believed that vascular changes in the retina reflect cerebral vascular changes.<sup>[6]</sup> Optical coherence tomography angiography (OCTA), a noninvasive method, can be used to measure the vascularity of the optic nerve head (ONH) and radial peripapillary capillaries (RPCs).<sup>[7]</sup> The use of dyes in fundus fluorescein angiography and the inadequate evaluation of the RPC network make the use of OCTA advantageous.<sup>[8]</sup>

Visual pathways are frequently affected in MS. As a result, approximately 50% of patients with MS experience visual

problems.<sup>[9]</sup> In addition, the first finding in 25% of these patients is decreased vision due to optic neuritis (ON).<sup>[10]</sup> In ON, axonal degeneration occurs as a result of demyelination of the optic nerve.<sup>[11]</sup> Visual evoked potential (VEP) is used in evaluating the visual pathways affected in MS. The prolongation of the p100 peak time (latency) in VEP measurement is considered to be an important finding in evaluating the destruction of the visual pathways. Based on the demyelination severity of these pathways, the p100 peak time in VEP starts to increase.<sup>[12,13]</sup> According to the International Society for Clinical Electrophysiology of Vision (ISCEV), the 60' measurement is the most valuable.<sup>[14]</sup> Postmortem examinations have revealed 94%–99% of visual damage in patients with MS.<sup>[15]</sup>

This study aims to determine the degree of damage to the visual pathways and to evaluate the effect of this damage on the vascular density (VD) in the ONH with OCTA. In other words, we aim to determine the relationship between neurodegeneration and vascular change in patients with MS. We also aim to determine the usability of OCTA, which is noninvasive, requires less patient compliance, is relatively inexpensive, and takes less time. We hope to obtain results that can predict neurodegeneration in visual pathways using OCTA measurements.

This is an open access journal, and articles are distributed under the terms of the Creative Commons Attribution-NonCommercial-ShareAlike 4.0 License, which allows others to remix, tweak, and build upon the work non-commercially, as long as appropriate credit is given and the new creations are licensed under the identical terms.

**For reprints contact:** WKHLRPMedknow\_reprints@wolterskluwer.com

**Cite this article as:** Ava S, Tamam Y, Hazar L, Karahan M, Erdem S, Dursun ME, *et al.* Relationship between optical coherence tomography angiography and visual evoked potential in patients with multiple sclerosis. *Indian J Ophthalmol* 2022;70:873-8.

### Access this article online

**Website:**  
www.ijo.in

**DOI:**  
10.4103/ijo.IJO\_431\_21

### Quick Response Code:



Dicle University School of Medicine, Department of Ophthalmology,  
<sup>1</sup>Dicle University School of Medicine, Department of Neurology,  
Diyarbakir, Turkey

**Correspondence to:** Dr. Leyla Hazar, Dicle University School of Medicine, Department of Ophthalmology Diyarbakir, Turkey. E-mail: drleylahazar@hotmail.com

Received: 23-Feb-2021

Revision: 06-Jul-2021

Accepted: 22-Sep-2021

Published: 25-Feb-2022

## Methods

The study was prospective and was conducted in accordance with the Declaration of Helsinki. Written informed consent was obtained from all patients included in the study. Approval for the study was received by the Dicle University Noninterventional Ethics Committee (Decision No. 234) on July 5, 2020.

Patients diagnosed with MS by a neurologist using the 2010 McDonald criteria were involved in this study.<sup>[16]</sup> Accordingly, 82 eyes of 41 patients diagnosed with MS were included. In addition, 52 eyes of 26 age-matched and sex-matched healthy patients were included as the control group. The control group was selected from individuals who applied to the eye outpatient clinic for a routine examination, had no systemic disease, and had no eye disease except  $\pm 2$  refractive error. The exclusion criteria were as follows: a) glaucoma and suspicion of glaucoma, b) visual acuity below 20/200, c) oral steroid treatment within 30 days, d) refractive error  $> \pm 3D$ , e) MS exacerbation within 30 days, f) intraocular infection, g) hypertensive or diabetic retinopathy, h) ischemic optic neuritis, and retinal vascular occlusion, i) refractive surgery history, and j) a fundus that could not be clearly visualized (corneal opacification, cataract, etc.). In addition, OCTA shots with a signal strength index (SSI) less than 50 and motion artifacts were not included.

The patients' names, sex, age, and duration of disease were recorded. Best-corrected visual acuity (BCVA) was determined according to the Snellen chart. Intraocular pressure was measured by applanation tonometry. Anterior segment and posterior segment examinations were performed using a slit lamp. The pupillary light reflex, RNFL analysis, and visual field were used to evaluate the optic nerve structurally and functionally with a complete ophthalmological examination. OCTA and VEP measurements of the participants were taken and recorded.

Humphrey Visual Field (Carl Zeiss Meditec, Inc.) was done using the SITA (Swedish interactive threshold algorithm) 24-2 protocols. The mean deviation (MD) was recorded.

### OCTA

Vascular measurements of the ONH were performed with an OCTA device (Optovue Inc., Fremont, CA, USA) using the RTVue XR-100 Avanti OCT and AngioVue software. This OCTA device has a scanning speed of 70,000 A per second with an 840 nm light source. B mode is formed by combining 304 A mode. The received scanning modes are processed according to the discrete spectrum amplitude decoration algorithm, and the image is created. The working principles of OCTA have been explained in detail in previous studies.<sup>[17]</sup> The area covered by the blood vessels in the region scanned using OCTA is called VD and is mapped.

In our study, the  $3.0 \times 3.0$  mm scanning mode was chosen for the ONH. VD measurement of the ONH and the area around the ONH of 3.45 mm (including RPCs) was performed [Figs. 1 and 2]. A whole image, an image of inside the optic disc, images of the peripapillary of the ONH, and of RPCs were taken.

### VEP

Measurements were recorded with a Monpack3 (Metrovision, France) VEP device in accordance with ISCEV.<sup>[18]</sup> The refraction

errors of the patients were corrected before starting the test. VEP recordings were recorded in a dark room and from both eyes separately. The duration (latency) and amplitude at the p100 peak value were recorded by providing the same conditions for all patients. Prolongation of p100 latency in the VEP 60' pattern is important for ON diagnosis in demyelinating diseases.<sup>[14]</sup> In accordance with the mean VEP p100 latency in a sample study and the control group, VEP p100 latency  $\geq 116$  ms was considered pathological.<sup>[19]</sup>

Based on these measurements, patients with MS were divided into two subgroups. Patients with MS with p100 latency  $\geq 116$  ms in VEP were included in group 1, and patients with MS with p100 latency  $< 116$  ms in VEP were included in group 2. The healthy controls were included in group 3.

### Statistical analysis

All statistical analyses were performed using the Statistical Package for the Social Sciences (SPSS) version 21 (SPSS, Inc., Chicago, IL). The normality of the data was verified using the Shapiro-Wilk test ( $P > 0.05$ ). A Chi-square test was used to determine the difference in patient ratios between the groups. Patients with MS were compared with the control group before being classified according to the prolongation of P100 latency in VEP. According to the normality test results, pairwise comparisons were made with the *t*-test or Mann-Whitney *U* test. A Pearson correlation test was used to analyze the relationship between parameters. A *P* value of less than 0.05 was considered statistically significant.

## Results

A total of 82 eyes of 41 patients with MS were included. Of the 41 patients with MS, 27 (65.9%) were women and 14 (34.1%) were men. The control group included 51 eyes of 26 healthy patients; 15 (57.6%) of the 26 controls were women and 11 (42.4%) were men ( $P = 0.338$ ) [Table 1]. One eye of a patient in the control group was not included in our study because the OCTA results were not satisfactory.

The average ages were  $38 \pm 6.4$  years in the MS group and  $36 \pm 3.4$  years in the control group ( $P = 0.063$ ). MS duration was  $7.3 \pm 9.0$  and  $5.5 \pm 4.7$  in groups 1 and 2, respectively. The difference between the groups was significant ( $P < 0.001$ ). The groups were also compared in terms of gender. The female:male ratio was 27:14 in MS group and 15:11 in control group ( $P = 0.338$ ).

The difference between groups was significant in terms of BCVA ( $P < 0.001$ ). When the groups were compared among themselves, there was a difference between all groups. The lowest vision was in group 1 [Table 1]. There was a significant difference between the groups in terms of p100 latency in VEP ( $P < 0.001$ ). When the groups were compared among themselves, the difference between all groups was significant ( $P = < 0.001$ ). The most prominent elongation in VEP was in group 1 [Table 2].

All RNFL values were found to be significantly lower when patients with MS were compared with the control group, regardless of the prolongation in P100 latency. In patients with MS with a P100 latency greater than 116 ms, the thinning of the RNFL was significant when compared with the group with a P100 latency below 116 ms and the control group. [Tables 2 and 3].

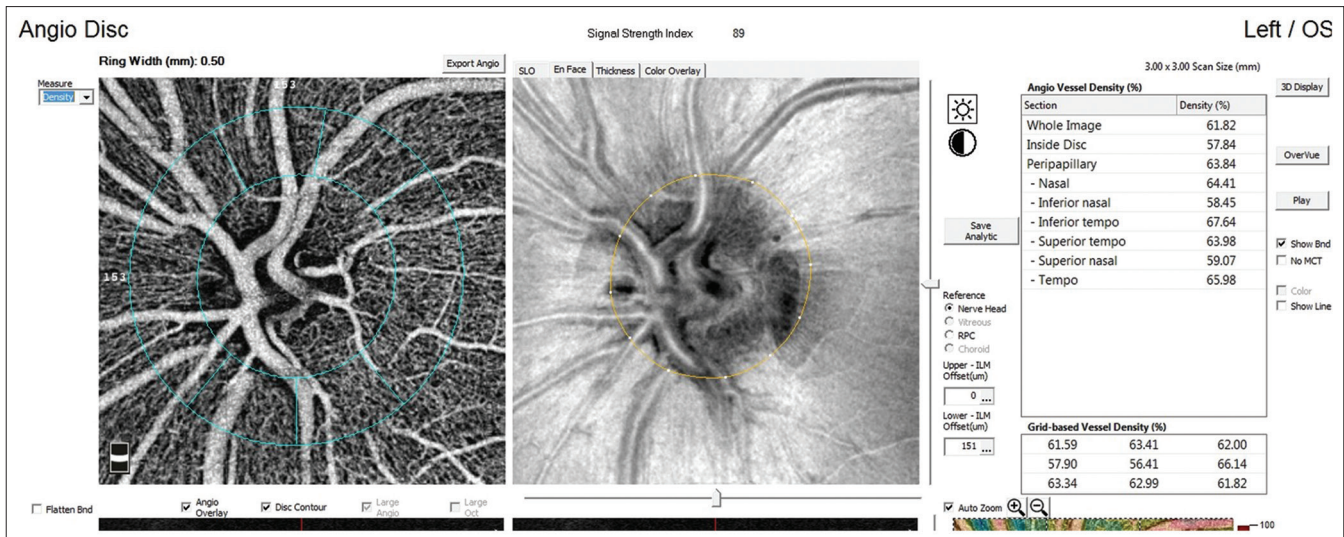


Figure 1: Vascular densities of the optic nerve head (ONH) were analyzed in images with a size of 3 mm x 3 mm centered on the optic disc

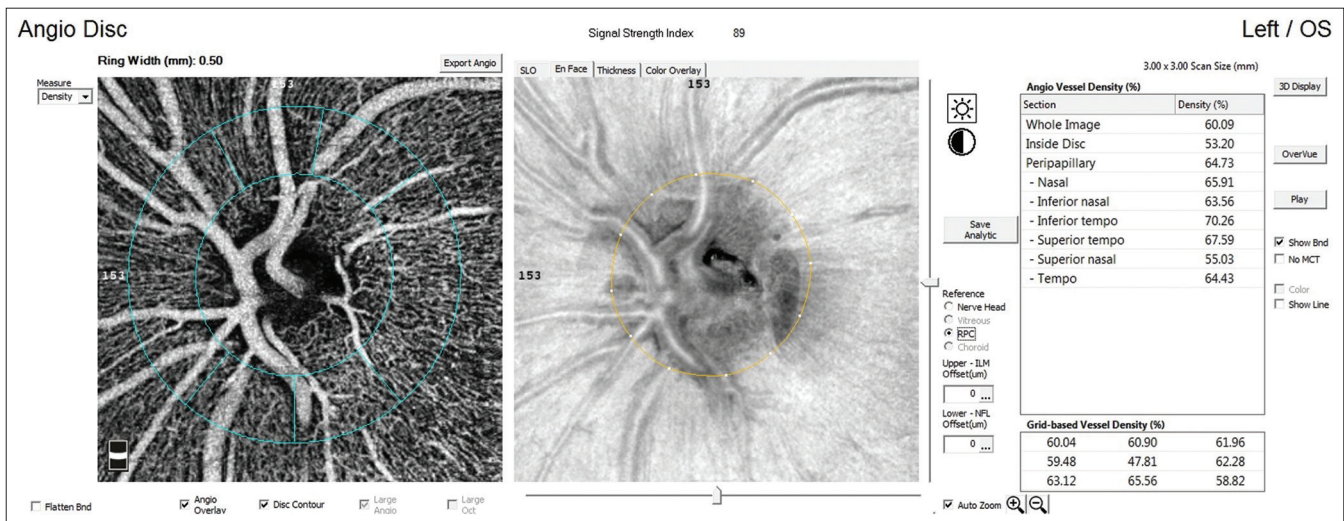


Figure 2: The radial peripapillary capillary (RPC) vessel densities were automatically measured within a 0.5-mm wide elliptical annulus extending outward from optic nerve head boundary

Regardless of the prolongation of P100 latency in patients with MS, whole image, inside disc ONH VD were found to be significantly lower than the control group ( $P = 0.002$ ,  $P = 0.001$ ,  $P = 0.004$ , respectively) [Table 2]. Peripapillary ONH VD was significantly lower in the group with p100 above 116 ms when the subgroup was made according to the prolongation of P100 latency in VEP ( $P = 0.047$ ,  $P = 0.037$ , respectively) [Table 4].

Regardless of the prolongation of P100 latency in patients with MS, whole image, inside disc, and peripapillary RPC VD were found to be significantly lower than the control group ( $P < 0.001$ ,  $P = 0.001$ ,  $P = 0.035$ ,  $P = 0.046$ ,  $P = 0.016$ , respectively) [Table 2]. Peripapillary RPC VD was significantly lower in the group with p100 latency above 116 ms when the VEP was subgrouped according to P100 latency prolongation ( $P = 0.019$ ,  $P = 0.025$ ,  $P = 0.006$ ,  $P = 0.022$ ,  $P = 0.036$  respectively) [Table 4]. Visual field MD value was significantly higher in patients with MS than in healthy controls ( $P < 0.001$ ) [Tables 2 and 3]. A significant correlation

was found between the values in all ONH VDs and in all sectors without RPC VD inside disc and the P100 value was detected in VEP [Table 5].

## Discussion

In our study, regardless of the prolongation P100 latency in VEP, whole image, and inside disc ONH VD and RPC VD, and RNFL decreased in all patients with MS compared with the control group, whereas those with delayed P100 latency peripapillary ONH VD and RPC VD and RNFL were affected according to controls and nondelayed p100 latency. When this was correlated with VEP, a statistically significant negative correlation was found between ONH VD and RPC VD and VEP.

MS is a disease characterized by neural degeneration due to inflammation in the CNS.<sup>[20]</sup> Vasculopathy develops in association with the disease and is seen in cerebral hypoperfusion. This condition is thought to be associated with disease progression.<sup>[21]</sup> Cerebral hypoperfusion has been demonstrated in both gray

and white matter.<sup>[22]</sup> However, studies conducted with many devices have reported that the ocular blood flow of patients with MS is also reduced.<sup>[23-25]</sup> Cerebral hypoperfusion is thought to have two causes. The first is arteriolar vasodilation caused by the disruption of the metabolism of cerebral astrocytes, and the other is a vascular change caused by neurodegeneration.<sup>[26]</sup> Other hypotheses considered in physiopathology are as follows: As the reduction in nerve fibers decreases metabolic demand in the tissue, blood flow decreases as an autoregulation mechanism, or vascular endotheliopathy occurs due to inflammation; therefore, hypoperfusion is thought to develop.<sup>[27]</sup> The reflection of this cerebral vascular change is seen in both the optic nerve and the retina.<sup>[28]</sup>

**Table 1: Comparison of age, gender, and visual acuity between groups**

	Patients with MS n=41	Control subjects n=26	P
Age (years)	38.0±6.4	36.0±3.4	*P=0.063
Gender Female/male	27/14	15/11	†0.338
BCVA	0.8±0.24	1.0±0.0	*P<0.001

\*t-test was used. †Chi-square test was used

**Table 2: Comparison of ONH VD and RPC VD values and RNFL thickness between patients with MS and control subjects**

	Patients with MS n=41	Control subjects n=26	*P
ONH VD			
Whole image	59.1±3.5	60.8±2.0	<b>0.002</b>
Inside disc	55.2±5.0	58.1±2.8	<b>0.001</b>
Peripapillary	62.1±3.9	63.1±2.4	0.084
RPC VD			
Whole image	56.9±4.1	59.4±2.2	<b>P&lt;0.001</b>
Inside disc	47.9±8.1	52.6±8.1	<b>0.001</b>
Peripapillary	63.0±5.1	64.6±2.7	<b>0.035</b>
VEP	119.0±17.9	102.4±4.8	<b>P&lt;0.001</b>
Visual field (md)	-5.15±3.32	-2.39±0.31	<b>P&lt;0.001</b>
RNFL average	96.0±13.3	101.4±10.3	<b>0.016</b>
RNFL superior	113.2±20.6	124.9±15.8	<b>0.001</b>
RNFL inferior	113.7±18.6	126.9±15.5	<b>P&lt;0.001</b>
RNFL temporal	70.5±7.8	79.3±7.1	<b>P&lt;0.001</b>
RNFL nasal	77.0±8.3	83.1±5.6	<b>P&lt;0.001</b>

†t-test was used, P<0.05 (denoted with bold) was statistically significant

Spain *et al.*<sup>[29]</sup> looked at the flow index of the ONH and found that the flow in the ONH decreased in patients with MS with and without ON. In addition, they reported that the decrease in ONH VD in patients with MS was higher in those with ON than in those without ON. Akarsu *et al.*<sup>[30]</sup> used Doppler ultrasonography to evaluate retrobulbar hemodynamics in patients with MS with ON. They found that the flow in the posterior ciliary artery and the central retinal artery was lower, particularly in eyes with ON compared with healthy eyes.

Farci *et al.*<sup>[31]</sup> found that capillary perfusion decreased in the optic disc in patients with MS, independent of ON. In our study, we determined that the VD in both ONH and RPC layers of the ONH of patients with MS was decreased compared with the control group, and the layer with the highest VD reduction was the RPC layer. In our study, the decrease in VD among the patient groups with MS was found to be significantly higher in the group with prolonged VEP p100 latency than in the group with normal VEP p100 latency. In other words, VD reduction in both the ONH and RPCs is significantly higher in patients with MS with ON than in patients with MS without ON. Whether the decrease in VD at the head of the optic disc in MS is a cause or a result of MS is still not fully explained. That is, it is not fully explained whether neurodegeneration causes decreased VD or whether decreased VD causes neurodegeneration. As seen in our study, these two conditions are interrelated.

Neurodegeneration in MS is manifested by optic nerve damage, reduced RNFL thickness, and reduced ganglion cell complex thickness.<sup>[32]</sup> Some studies suggest using this thickness loss as a biomarker for neurodegeneration.<sup>[33,34]</sup> In addition, some studies report a negative correlation between RNFL thickness and p100 elongation in VEP.<sup>[35,36]</sup> As is known, the most important examination to show neurodegeneration in the visual pathways is VEP.<sup>[37]</sup> Therefore, in our study, we evaluated the visual pathways with VEP in patients without a history of ON.

In our study, decreased RNFL thickness was significant in group 1 because these patients had ON damage. Simultaneously, there was prolongation in the VEPs of patients in this group. The purpose of studying VEP was to detect ON damage because postmortem studies have reported that ON damage is present in patients with MS without visual complaints.<sup>[14]</sup>

As is known, there are disadvantages relating to VEP, such as the length of time it takes to perform VEP analysis and not being able to perform VEP analysis of patients whose visual acuity is below 20/200 based on the Snellen chart.<sup>[38]</sup> In this case, we thought it would be advantageous to use the noninvasive method of OCTA to measure vascularity in the ONH. We

**Table 3: Comparison of retinal nerve fiber layer thickness between three groups**

	Group 1 (ON)	Group 2 (without ON)	Group 3 (controls)	P		
				Group 1-2	Group 2-3	Group 1-3
Visual field (MD)	-5.48±3.70	-4.94±3.07	-2.39±0.31	0.484	<b>&lt;0.001</b>	<b>&lt;0.001</b>
RNFL Average	88.5±15.7	100.8±8.7	101.5±10.3	<b>&lt;0.001</b>	0.825	<b>&lt;0.001</b>
RNFL Superior	100.1±19.9	121.6±16.0	125.1±15.9	<b>&lt;0.001</b>	0.329	<b>&lt;0.001</b>
RNFL Inferior	101.0±20.8	121.9±10.9	127.0±15.6	<b>&lt;0.001</b>	0.072	<b>&lt;0.001</b>
RNFL Temporal	67.2±10.0	72.6±5.0	79.5±7.0	<b>0.002</b>	<b>&lt;0.001</b>	<b>&lt;0.001</b>
RNFL Nasal	71.7±8.7	80.3±5.9	79.4±7.9	<b>&lt;0.001</b>	<b>0.027</b>	<b>&lt;0.001</b>

**Table 4: Comparison of optic nerve head (ONH) VD and radial peripapillary capillaries (RPC) VD between subgroups**

	Group 1 n=32 eyes	Group 2 n=50 eyes	Group 3 n=51 eyes	*P		
				Group 1-2	Group 2-3	Group 1-3
<b>ONH VD</b>						
Whole image	58.5±3.7	59.6±3.0	60.8±2.0	0.136	<b>0.023</b>	<b>&lt;0.001</b>
Inside disc	54.9±6.6	55.3±3.8	58.1±2.8	0.742	<b>&lt;0.001</b>	<b>0.003</b>
Peripapillary	61.0±4.0	62.8±3.7	63.1±2.4	<b>0.047</b>	0.563	<b>0.003</b>
<b>RPC VD</b>						
Whole image	56.2±4.9	57.4±3.4	59.4±2.2	0.180	<b>0.001</b>	<b>&lt;0.001</b>
Inside disc	49.1±8.3	47.1±8.0	52.6±8.1	0.273	<b>0.001</b>	<b>0.060</b>
Peripapillary	61.3±5.3	64.1±4.7	64.6±2.7	<b>0.019</b>	0.456	<b>&lt;0.001</b>

\*t-test was used, P<0.05 (denoted with bold) was statistically significant

**Table 5: Correlation between VEP and ONH VD and RPC VD**

Pearson correlation	r	P
<b>VEP and ONH VD</b>		
Whole image	-0.320	<b>P&lt;0.001</b>
Inside disc	-0.250	<b>P=0.004</b>
Peripapillary	-0.303	<b>P&lt;0.001</b>
<b>VEP and RPC VD</b>		
Whole image	-0.335	<b>P&lt;0.001</b>
Inside disc	-0.083	<b>P=0.340</b>
Peripapillary	-0.352	<b>P&lt;0.001</b>

P<0.05 was statistically significant (denoted with bold)

found a negative correlation between VD and VEP in all sectors except the ONH superonasal sector and RPCs inside the optic disc. In other words, we found that the vascularity of the ONH and RPCs decreased in patients with MS with prolonged VEP p100 latency.

### Conclusion

In conclusion, we would like to emphasize that the ONH VD and RPC VD in the OCTA of patients with MS are correlated with VEP, in addition, vascular density measurement in OCTA can show optic nerve involvement. As the use of OCTA in these patients becomes routine, we will acquire more information.

### Financial support and sponsorship

Nil.

### Conflicts of interest

There are no conflicts of interest.

### References

- Uher T, Vaneckova M, Sormani MP, Krasensky J, Sobisek L, Dusankova JB, et al. Identification of multiple sclerosis patients at highest risk of cognitive impairment using an integrated brain magnetic resonance imaging assessment approach. *Eur J Neurol* 2017;24:292-301.
- Hyun JW, Park G, Kwak K, Jo HJ, Joung, A, Kim JH, et al. Deep gray matter atrophy in neuromyelitis optica spectrum disorder and multiple sclerosis. *Eur J Neurol* 2017;24:437-45.
- Weiner HL. Multiple sclerosis is an inflammatory T-cell-mediated autoimmune disease. *JAMA Neurol* 2004;61:1613-5.
- Modrego PJ, Pina MA. Trends in prevalence and incidence of

- multiple sclerosis in Bajo Aragon, Spain. *J Neurol Sci* 2003;216:89-93.
- Lanzillo R, Cennamo G, Criscuolo C, Carotenuto A, Velotti N, Sparnelli F, et al. Optical coherence tomography angiography retinal vascular network assessment in multiple sclerosis. *Mult Scler* 2018;24:1706-14.
- Byerly MS, Blackshaw S. Vertebrate retina and hypothalamus development. *Wiley Interdiscip Rev Syst Biol Med* 2009;1:380-9.
- Cennamo G, Romano MR, Vecchio EC, Minervino C, Della Guardia C, Velotti N, et al. Anatomical and functional retinal changes in multiple sclerosis. *Eye (Lond)* 2016;30:456-62.
- Falavarjani KG, Tian JJ, Akil H, Garcia GA, Sadda SR, Sadun AA. Swept-source optical coherence tomography angiography of the optic disk in optic neuropathy. *Retina* 2016;36:S168-77.
- Takemura MY, Hori M, Yokoyama K, Hamasaki N, Suzuki M, Kamagata K, et al. Alterations of the optic pathway between unilateral and bilateral optic nerve damage in multiple sclerosis as revealed by the combined use of advanced diffusion kurtosis imaging and visual evoked potentials. *Magn Reson Imaging* 2016;39:24-30.
- Toosy AT, Mason DF, Miller DH. Optic neuritis. *Lancet Neurol* 2014;13:83-99.
- Compston A, Coles A. Multiple sclerosis. *Lancet* 2008;372:1502-17.
- Janáky M, Jánosy Á, Horváth G, Benedek G, Braunitzer G. VEP and PERG in patients with multiple sclerosis, with and without a history of optic neuritis. *Doc Ophthalmol* 2017;134:185-93.
- Calugaru L, Calugaru GT, Calugaru OM. Evoked potentials in multiple sclerosis diagnosis and management. *Curr Health Sci J* 2016;42:385-9.
- Odom JV, Bach M, Brigell M, Holder GE, McCulloch DL, Mizota A, et al. ISCEV standard for clinical visual evoked potentials: (2016 update). *Doc Ophthalmol* 2016;133:1-9.
- Saidha S, Sotirchos ES, Oh J, Syc SB, Seigo MA, Shiee N, et al. Relationships between retinal axonal and neuronal measures and global central nervous system pathology in multiple sclerosis. *JAMA Neurol* 2013;70:34-43.
- Polman CH, Reingold SC, Banwell B, Clanet M, Cohen JA, Filippi M, et al. Diagnostic criteria for multiple sclerosis: 2010 revisions to the McDonald criteria. *Ann Neurol* 2011;69:292-302.
- Turgut B. "Optical coherence tomography angiography—A general view. *Eur Ophthalmic Rev* 2016;10:39-42.
- Robson AG, Nilsson J, Li S, Jalali S, Fulton AB, Tormene AP, et al. ISCEV guide to visual electrodiagnostic procedures. *Doc Ophthalmol* 2018;136:1-26.
- Niklas A, Sebraoui H, Hess E, Wagner A, Then Bergh F. Outcome measures for trials of remyelinating agents in multiple sclerosis: Retrospective longitudinal analysis of visual evoked potential latency. *Mult Scler* 2009;15:68-74.

20. Herranz E, Gianni C, Louapre C, Treaba CA, Govindarajan ST, Ouellette R, *et al.* Neuroinflammatory component of gray matter pathology in multiple sclerosis. *Ann Neurol* 2016;80:776-90.
21. Monti L, Morbidelli L, Rossi A. Impaired cerebral perfusion in multiple sclerosis: Relevance of endothelial factors. *Biomark Insights* 2018;13:1177271918774800. doi: 10.1177/1177271918774800.
22. D'haeseleer M, Hostenbach S, Peeters I, Sankari SE, Nagels G, De Keyser J, *et al.* Cerebral hypoperfusion: A new pathophysiologic concept in multiple sclerosis?. *J Cereb Blood Flow Metab* 2015;35:1406-10.
23. Sugiyama T, Araie M, Riva CE, Schmetterer L, Orgul S. Use of laser speckle flowgraphy in ocular blood flow research. *Acta Ophthalmol* 2010;88:723-9.
24. Peng Q, Zhang Y, Nateras OS, van Osch MJ, Duong TQ. MRI of blood flow of the human retina. *Magn Reson Med* 2011;65:1768-75.
25. Mitchell DG. Color Doppler imaging: Principles, limitations, and artifacts. *Radiology* 1990;177:1-10.
26. Marrie RA, Rudick R, Horwitz R, Cutter G, Tyry T, Campagnolo D, *et al.* Vascular comorbidity is associated with more rapid disability progression in multiple sclerosis. *Neurology* 2010;74:1041-7.
27. Oertel FC, Zimmermann HG, Brandt AU, Paul F. Novel uses of retinal imaging with optical coherence tomography in multiple sclerosis. *Expert Rev Neurother* 2019;19:31-43.
28. Jiang H, Delgado S, Liu C, Rammohan KW, DeBuc DC, Lam BL, *et al.* *In vivo* characterization of retinal microvascular network in multiple sclerosis. *Ophthalmology* 2016;123:437-8.
29. Spain RI, Liu L, Zhang X, Jia Y, Tan O, Bourdette, D, *et al.* Optical coherence tomography angiography enhances the detection of optic nerve damage in multiple sclerosis. *Br J Ophthalmol* 2018;102:520-4.
30. Akarsu C, Tan FU, Kendi T. Color Doppler imaging in optic neuritis with multiple sclerosis. *Graefes Arch Clin Exp Ophthalmol* 2004;42:990-4.
31. Farci R, Carta A, Cocco E, Frau J, Fossarello M, Diaz G. Optical coherence tomography angiography in multiple sclerosis: A cross-sectional study. *PLoS One* 2020;15:e0236090.
32. Bhaduri B, Nolan RM, Shelton RL, Pilutti LA, Motl RW, Moss HE, *et al.* Detection of retinal blood vessel changes in multiple sclerosis with optical coherence tomography. *Biomed Opt Express* 2016;7:2321-30.
33. Petzold A, Balcer LJ, Calabresi PA, Costello F, Frohman TC, Frohman EM, *et al.* Retinal layer segmentation in multiple sclerosis: A systematic review and meta-analysis. *Lancet Neurol* 2017;16:797-812.
34. Nolan RC, Akhand O, Rizzo JR, Galetta SL, Balcer LJ. Evolution of visual outcomes in clinical trials for multiple sclerosis disease-modifying therapies. *J Neuroophthalmol* 2018;38:202-9.
35. DI Maggio G, Santangelo R, Guerrieri S, Bianco M, Ferrari L, Medagliani S, *et al.* Optical coherence tomography and visual evoked potentials: Which is more sensitive in multiple sclerosis? *Mult Scler* 2014;20:1342-7.
36. Yilmaz H, Ersoy A, Icel E. Assessments of vessel density and foveal avascular zone metrics in multiple sclerosis: An optical coherence tomography angiography study. *Eye* 2020;34:771-8.
37. Yang EB, Hood DC, Rodarte C, Zhang X, Odel JG, Behrens MM. Improvement in conduction velocity after optic neuritis measured with the multifocal VEP. *Invest Ophthalmol Vis Sci* 2007;48:692-8.
38. Creel DJ. Visually evoked potentials. *Handb Clin Neurol* 2019;160:501-22.