Doc Ophthalmol
https://doi.org/10.1007/s10633-020-09802-y

CLINICAL CASE REPORT

Long-chain 3-hydroxyacyl-CoA dehydrogenase (LCHAD) deficiency and progressive retinopathy: one case report followed by ERGs, VEPs, EOG over a 17-year period

Florence Rigaudière · Eliane Delouvrier · Jean-François Le Gargasson · Paolo Milani · Hélène Ogier de Baulny · Manuel Schiff

Received: 29 May 2020 / Accepted: 27 October 2020
© Springer-Verlag GmbH Germany, part of Springer Nature 2021

Abstract

Background LCHAD (long-chain 3-hydroxyacyl-CoA dehydrogenase) deficiency is a rare genetic disorder of mitochondrial long-chain fatty acid oxidation inherited as a recessive trait. Affected patients can present with hypoglycaemia, rhabdomyolysis and cardiomyopathy. About half of the patients may suffer from retinopathy.

Case report A 19-year-old girl was diagnosed as suffering from LCHAD deficiency with recurrent rhabdomyolysis episodes at the age of 7 months by an inaugural coma with hypoglycaemia and hepatomegaly. Appropriate dietary management with carnitine supplementation was initiated. Retinopathy was diagnosed at age two. Ophthalmological assessments including visual acuity, visual field, OCT, flash ERGs, P-ERG, flash VEPs and EOG recordings were conducted over a 17-year period.

Results Visual acuity was decreased. Fundi showed a progressive retinopathy and chorioretinopathy. Photophobia was noticed 2 years before the decrease in photopic-ERG amplitude with normal scotopic-ERGs. Scotopic-ERG amplitude decreased 10 years after the decrease in photopic-ERG amplitude. No EOG light rise was observed. Flash VEPs remained normal. These results suggest that the cone system dysfunction occurs largely prior to the rod system dysfunction with a relative preservation of the macula function.

Comments This dysfunction of cones prior to the dysfunction of rods was not reported previously. This could be related to mitochondrial energy failure in cones as cones are greater consumers of ATP than rods. This hypothesis needs to be further confirmed as other long-chain fatty oxidation defective patients (VLCAD and CPT2 deficiencies) do not exhibit retinopathy.

Keywords LCHAD-deficiency · Retinopathy · Photopic-ERG deficiency preceding scotopic-ERG · Cone ATP deficiency

F. Rigaudière (✉) · J.-F. Le Gargasson · P. Milani
Service de Physiologie Clinique, Exploration Fonctionnelle, Hôpital Lariboisière, AP-HP, Paris, France
e-mail: rigaudiereflo@aol.com

F. Rigaudière · J.-F. Le Gargasson · H. Ogier de Baulny
Faculté de Médecine Paris-Diderot, Université de Paris, Paris, France

E. Delouvrier
Service d'Ophtalmologie, Hôpital Robert Debré, AP-HP, Paris, France

H. Ogier de Baulny · M. Schiff
Reference Center for Inborn Errors of Metabolism, Robert Debré Hospital, AP-HP, Paris, France

M. Schiff
Reference Center for Inborn Errors of Metabolism, Faculté de Médecine Paris-Descartes, Necker University Hospital, AP-HP, Université de Paris, Paris, France

M. Schiff
Institut Imagine, Inserm UMRS_1163, Paris, France

Published online: 04 January 2021

Abbreviations

EOG	Electro-oculogram
ERG	Electroretinogram
LCHAD-D	Long-chain 3-hydroxyacyl-coenzyme A dehydrogenase
LE	Left eye
OCT	Optical coherent tomography
P-ERG	Pattern-electroretinogram
RE	Right eye
RPE	Retinal pigment epithelium
VEP	Visual evoked potential

Introduction

Mitochondrial fatty acid oxidations play a central role in energy metabolism of the organism [1]. One of the enzymes involved in long-chain fatty acid oxidation is the mitochondrial trifunctional protein which catalyses the last three steps of the beta-oxidation of long-chain fatty acids [2]. This enzyme is composed of 4 alpha and 4 beta subunits, respectively, encoded by the *HADHA* and *HADHB* genes. The alpha subunit harbours the 3-hydroxyacyl-CoA dehydrogenase and enoyl-CoA hydratase activities, whereas the beta subunit harbours the 3-ketoacyl-CoA thiolase activity [3].

Deficiencies of the enzyme activities of the mitochondrial trifunctional protein are rare and can be classified biochemically in two forms [4]. The first form has been described in few patients where all three enzyme activities of the mitochondrial trifunctional protein are deficient (MTP-deficiency). The second form corresponds to the 3-hydroxyacyl-CoA dehydrogenase deficiency (LCHAD-D), third step of the beta-oxidation associated with normal hydratase activity and slightly decreased thiolase activity [3].

LCHAD-D is a rare autosomal recessive inborn error of mitochondrial fatty acid beta-oxidation [1, 5]. The c.1528G > C variant in *HADHA* is frequently observed [3, 6]. It can present during the neonatal period or during infancy with sudden death, hepatopathy, hypoglycaemia, rhabdomyolysis, myopathy and cardiomyopathy [7]. Two complications have been described: peripheral neuropathy in 5–10% of patients and pigmentary retinopathy. At least 50% of patients develop retinopathy [8] with progressive chorioretinal atrophy and loss of visual acuity [7], but the true incidence is not known.

Our objective is to present the progressive retinopathy in one LCHAD-D girl followed by ERGs, VEPs, P-ERG and EOG over a 17 year-period.

Subject L.

L. is a 19-year-old female. She was born at term following an uncomplicated pregnancy and delivery from healthy, non-consanguineous parents. She was diagnosed as suffering from LCHAD-D at the age of 7 months following coma with hypoglycaemia and hepatomegaly thanks to suggestive plasma acylcarnitine profile. LCHAD-D was confirmed by enzyme and molecular analyses when she was 13 months old. She was compound heterozygous for the frequent variant c.1528G > C (p.Glu510Gln) and a nonsense variant c.1195 C > T (p.Arg399*) in *HADHA*. Treatment included avoidance of fasting, low-fat diet (20–25% of daily energy intake) mainly as medium chain triglycerides. Carnitine and DHA supplementation was also initiated. She complained of muscular pain and recurrent rhabdomyolysis episodes at the time of infections (on average, 1 hospitalization per year for metabolic decompensations between diagnosis and 5 years of age) or prolonged physical exercise (on average, 1 hospitalization every 2 years for decompensations, mainly myolysis between age 5 and age 12 and 1 hospitalization every 3 years between age 12 and age 19). Clinical examination revealed moderate hepatomegaly. There was no cardiomyopathy. Peripheral neuropathy was clinically present early on because of abolition of all deep-tendon reflexes and formally diagnosed by electrophysiology at age 19 [9]. She exhibited mild learning difficulties albeit normal cognitive outcome.

Ophthalmological examination was normal at the age of 6 months. Retinopathy was first detected at the age of 12 months. Her fundi showed granular pigmentations in the macula and focal pigmentary aggregations along the retinal vessels. This retinopathy was classified stage 2 according to Tyni (1998) [10]. A mild exophoria was noted at the age of 4 years. Visual acuity was 20/40 in the right eye with − 1 dt, and 20/30 in the left one with − 1.25 dt at the age of 7 years. The patient did not complain of hemeralopia but of photophobia in bright light. Visual acuity was

20/50 in the right and left eyes at the age of 12 years, with a small myopia progression: − 1.75 dt in the right eye and − 2.25 dt in the left eye. Her binocular vision was good. She exhibited no visuospatial deficiency. Her visual acuity was slightly decreased: 20/70 in the right eye and 20/50 in the left one at the age of 16 years. Her myopia was stable. Her fundi showed severe chorioretinal atrophy, and she complained of night blindness. Visual acuity was 20/100 in the right and left eyes at the age of 19 years. Myopia had slightly increased. She wore sunglasses against bright light.

Materials and methods

Fundus colour retinographies and Goldmann visual fields were obtained at the age of 12 and 16 years. OCT was performed with a Zeiss device Cirrus HD-OCT 5000 at the age of 16 years.

Seven flash ERGs and VEPs were recorded when she was 2, 5, 7, 12, 15, 16 and 19 years old. EOG was recorded at the age of 12 and 16 years. Electrophysiological full field device used was a MonColor system (Metrovision, 59 Perenchies, France). All procedures were conducted according to ISCEV standard protocols: flash ERGs [11], P-ERG [12], EOG [13] and flash VEPs [14].

Flash ERG recordings. L. was never sedated. Her pupils were fully dilated. Child size corneal electrodes were used at the age of 2 years and skin electrodes for the further recordings (Comepa, Neurocom, 93 Bagnolet, France) [15, 16]. The two active electrodes were applied on each inferior eyelid. The reference electrode was placed on the forehead. The two earlobes were connected to the ground. Before each ERG recording, L. was dark-adapted for 20 mn. The two dark-adapted flash ERG responses were then recorded, i.e. rod-response to dim white flash and mixed-response to bright standard flash. After 10 mn of light adaptation to a white background (30 cd/m^2), the three light-adapted flash ERG responses were recorded to bright standard flash, i.e. photopic oscillatory potentials (Phot-OPs—100–300 Hz), cone-response and flicker-response (30 Hz).

Flash VEPs were recorded with two active scalp electrodes placed on 01 and 02 [17]. Fifty stimulations were delivered binocularly and monocularly to the right and the left eye. Two successive recordings were performed to verify the reproducibility of each VEP. Analysis time was 750 ms to visualize the response adequately.

P-ERG was recorded with natural pupil sizes and optimal refraction. Each active skin electrode was applied on each inferior eyelid. The reference electrode was placed on forehead. The two earlobes were connected to the ground. P-ERGs were recorded at the age of 7, 12 and 16 years (check size 40′–2 Hz).

EOGs were recorded at the age of 12 and 16 years.

Results

Retinographies. At the age of 12 years, chorioretinal atrophy was seen on the posterior pole with increased clustered hyperpigmentation of the whole retina. The papillae were normal. The retinopathy was classified stage 3 according to Tyni [10] (Fig. 1). At the age of 16 years, chorioretinal atrophy was severe with constricted vessels. The autofluorescence retinographies showed atrophic neuroretina and pigment epithelium, revealing the choriocapillary. The papillae were homogeneous and fluorescent which is unusual (Fig. 2). *Goldman visual field* was in the normal range at the age of 12 years. It showed an annular scotoma at the age of 16 years (Fig. 3). OCT at the age of 16 years (Fig. 4): the neuroretina thickness was within normal with preservation of the foveal pits. As the line of photoreceptors was difficult to see, it was not possible to appreciate possible photoreceptor modifications. The pigment epithelium appeared more transparent than normal it means possibly thinner. The fundi showed bilateral choriocapillary atrophy.

Flash ERGs (Figs. 5 and 6). Seven ERGs were recorded between the ages of 2 and 19. At the age of 2, flash ERG was normal. At the age of 5 and 7, rod- and mixed-responses were normal, Phot-OPs and cone-response were normal, and the amplitude of the flicker-response was decreased. At age 12 years, amplitude of all photopic responses (Phot-OPs, cone-response, flicker-response) was significantly decreased, and the scotopic responses were modified: the amplitude of b-wave rod-response was decreased, a-wave mixed-response was absent, and implicit time of b-wave mixed-responses was increased. At the age of 15 and 16 years, all scotopic and photopic response amplitudes were decreased. At the age of 19 years,

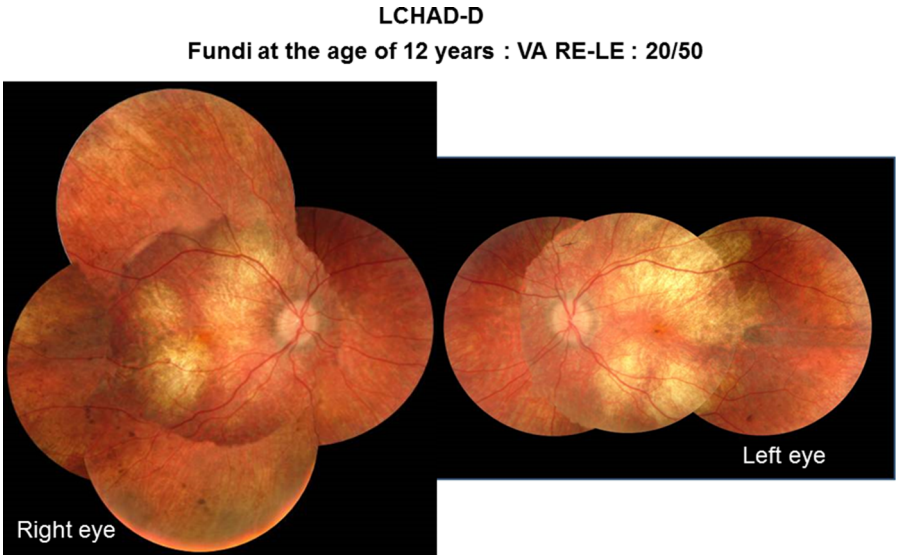

Fig. 1 L. LCHAD-D. Fundi at the age of 12 years. Visual acuity right and left eye: 20/50

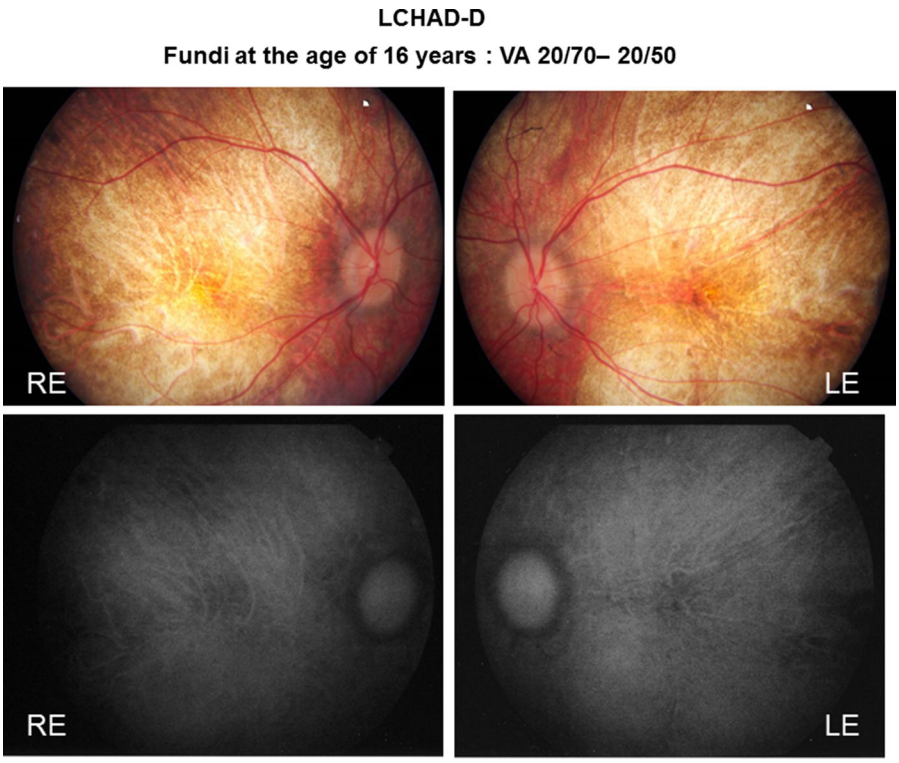

Fig. 2 L. LCHAD-D. Fundi at the age of 16 years. Color and autofluorescent retinographies. Atrophic retinas. Unusual fluorescent papillae

scotopic and photopic responses were barely discernible.

P-ERG and flash VEPs (Fig. 7). Right and left eye flash VEPs were symmetrical. They were normal at the age of 2 years. P-ERG was normal, and flash VEPs were within normal at the age of 7 years. P-ERG amplitudes were decreased at the age of 12 years and non-discernible at the age of 16 years. Flash VEPs

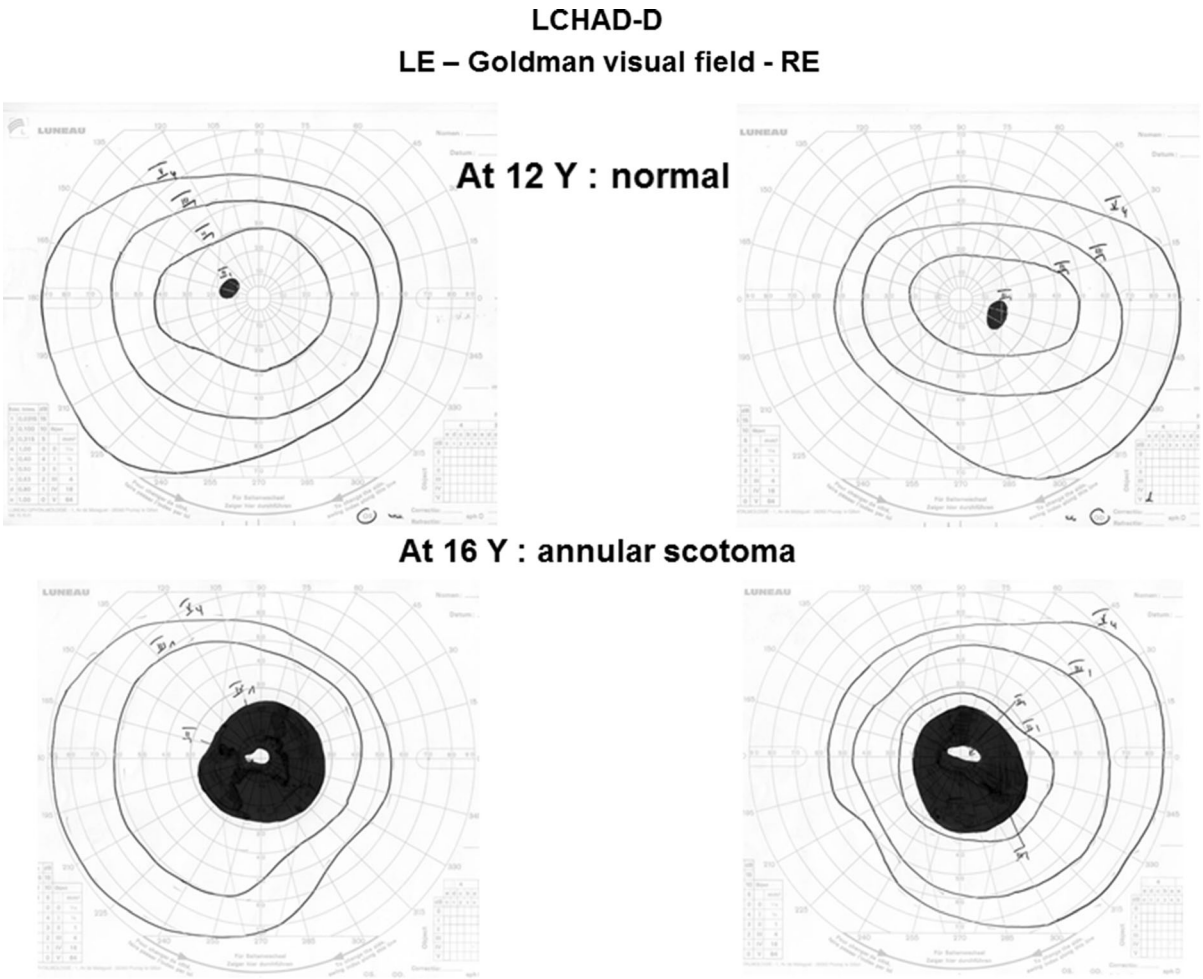

Fig. 3 L. LCHAD-D. Goldmann visual field: normal at the age of 12 with annular scotoma at the age of 16 years

remained discernible but with slightly decreased amplitudes at the age of 12 and 16 years.

EOG had no Light Peak at the age of 12 and 16 years.

Comments

Although poor functional outcome has been reported in LCHAD-D [5, 18], the patient herein presented had a good quality of life thanks to appropriate therapeutic management [18, 19]. While such management including DHA supplementation which might slow down eye disease progression [20] is clearly beneficial in decreasing the episodes of metabolic decompensations [7, 21], it has no or little impact on the evolution of the pigmentary retinopathy towards a severe chorioretinopathy [21]. Stopek et al. [22] even described a rare case of bilateral macular choroidal neovascularization in a 9-year-old girl. The retinopathy of our patient evolved similarly to other cases of LCHAD-D retinopathy. We observed the retinopathy evolution from stage 2 at the age of 2 years, to stage 3 at the age of 12 and 16 years. At these ages, her retinographies showed pigment epithelium and choriocapillary atrophies [6]. At age 16 years, the retinal thickness seemed preserved as OCT was nearly normal.

At the age of 5 years, the amplitude of the flicker-response was decreased. The other ERG responses were normal. At the age of 7 years, L. showed signs of photophobia. This sign indicated a dysfunction of the photopic system as in achromatopsia [23]. In fact, photophobia in our patient corresponded to a very mild

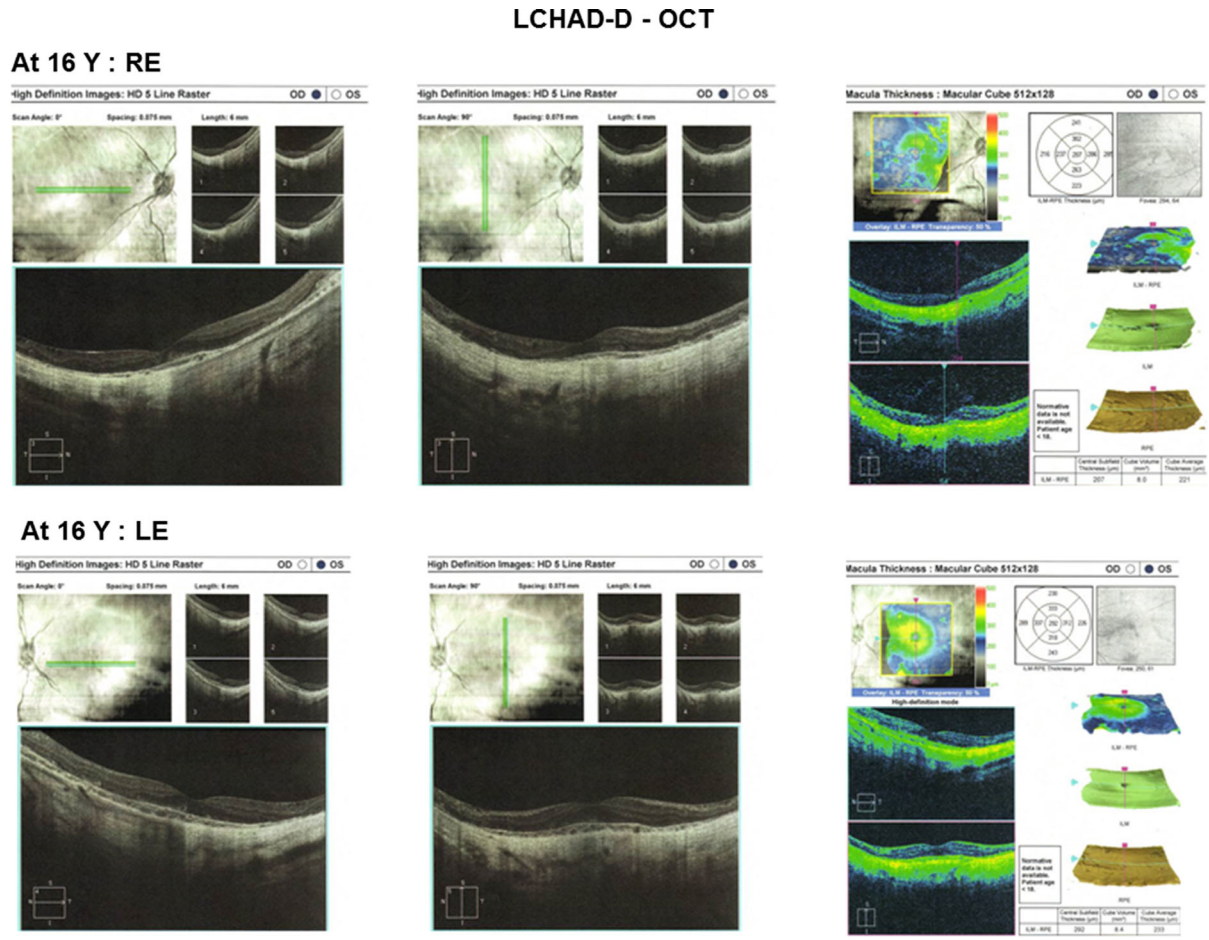

Fig. 4 L. LCHAD-D. RE and LE OCT at the age of 16 years. Normal thickness. Preservation of foveal pit. RPE transparency, choriocapillary atrophy

amplitude decrease of her flicker-responses. Signs of photophobia were observed almost 5 years before the amplitude decrease of the photopic system was confirmed at the age of 12 years. At the age of 7 years, the functioning of her macular areas remained normal. This was attested by normal P-ERG and normal VEP and could explain why her visual acuity remained almost normal.

At the age of 12 years, photopic response amplitudes were strongly decreased, even non-discernible while scotopic response amplitudes were decreased moderately. P-ERG amplitude decreased suggesting that the macular areas were dysfunctioning which is a normal consequence of the dysfunction of the photopic system. Flash VEPs were still discernible suggesting that foveas were continuing to function moderately. Visual acuity remained stable.

Tyni et al. [24] and Boese et al. [25] suggested that RPE was early affected and that photoreceptors degeneration may be secondary. LCHAD-D RPE model created by Polinati et al. [26] revealed the important contribution of RPE disorganization by LCHAD deficiency to LCHAD-D retinopathy. It is not possible to confirm the role of RPE by electrophysiological testing. The only electrophysiological test of the RPE is EOG. However, to be valid, it is necessary that the rods function normally as rod signals are the EOG trigger. At the age of 12 years, EOG had no light peak, but the absence of a-wave mixed-response deprived EOG of its trigger. Therefore, it was not possible to assess by this means the state of dysfunction or not of the pigment epithelium. However, RPE was very likely dysfunctioning as shown on the retinographies.

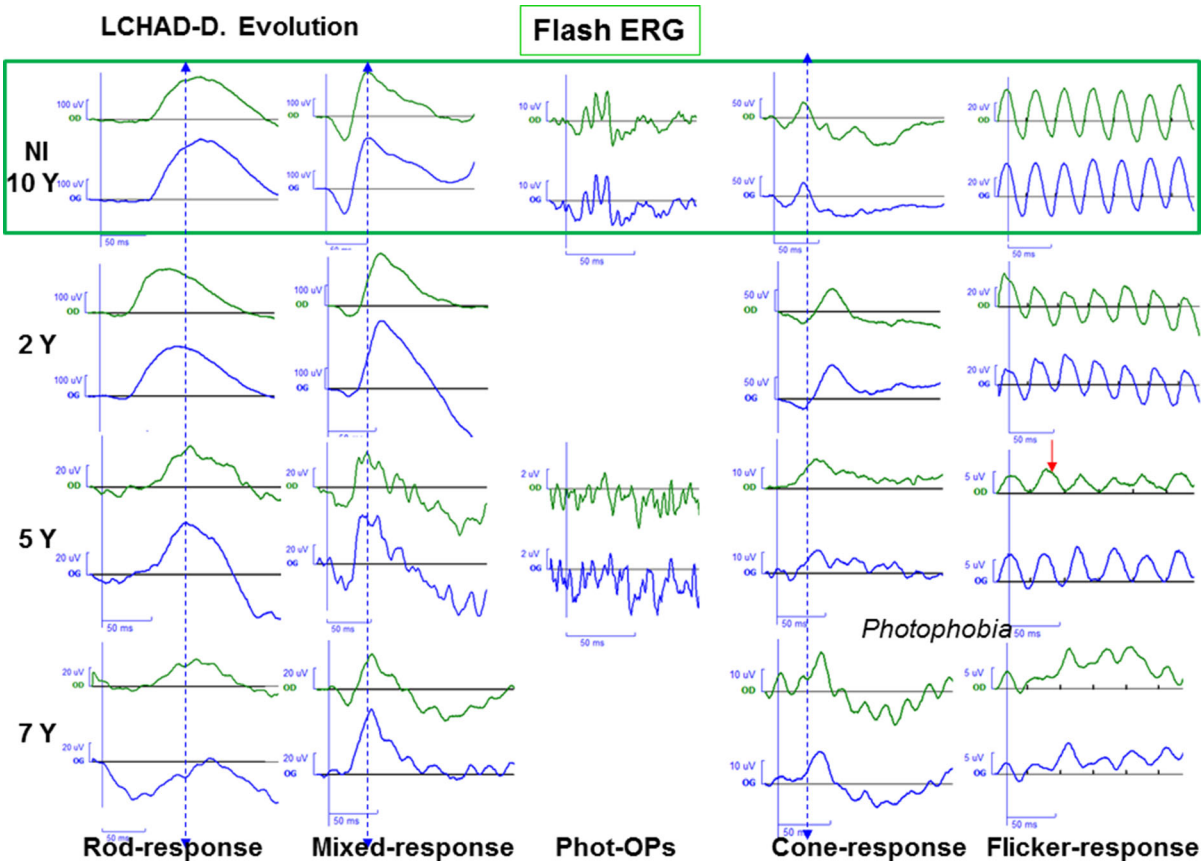

Fig. 5 L. LCHAD-D. Evolution of the standard flash ERG between the age of 2 and 7 years. Amplitude of the photopic responses was progressively decreased. Nearly normal scotopic responses. Right eye: green line Left eye: blue line

At the age of 12 years, visual field was normal as found on Tyni's subject L1 at 7 years and subject L4 at 5 years [24]. At the age of 16 years, our patient had a major dysfunction of the photopic and scotopic systems. Her visual field presented an annular scotoma with central sparing similar to that of Tyni's subject L2 at 13 years. The evolution of our subject's visual field is very similar to that observed in Tyni's subject L2. This annular scotoma would correspond to the area of Bjerum where density of rods is maximum. We remind that the visual field checks cone sensitivities. The important trophic role of rods on cone function is known by means of the rod-derived cone viability factor [27]. Rod dysfunction had a localized effect on the cone function. Thus cone deficiency was probably majored in this Bjerum area as rods were deficient and may explain the annular localization of the scotoma in the visual field.

Few ERGs and/or VEP have been recorded on young LCHAD-D patients [10, 20, 28, 29]. These authors report that most ERGs progressively deteriorate during the first decade of life. However, they have not described which categories of responses were initially deficient. Boese et al. [25] followed the evolution of flash ERGs of 18 LCHAD-D patients over a long period. From the average age of 7 years, the photopic and scotopic responses of their patients seem to decrease in a parallel way. This is not the case in the results recorded on our patient.

All of our results were recorded over a 17 year-period using the same stimulations, equipment, procedures and interpreters. They have allowed us to follow the evolution of the photopic and scotopic retina systems in a reliable way.

As previously reported, we have found that the evolution of our patient's retinopathy was inexorable. However, we have shown for the first time that the

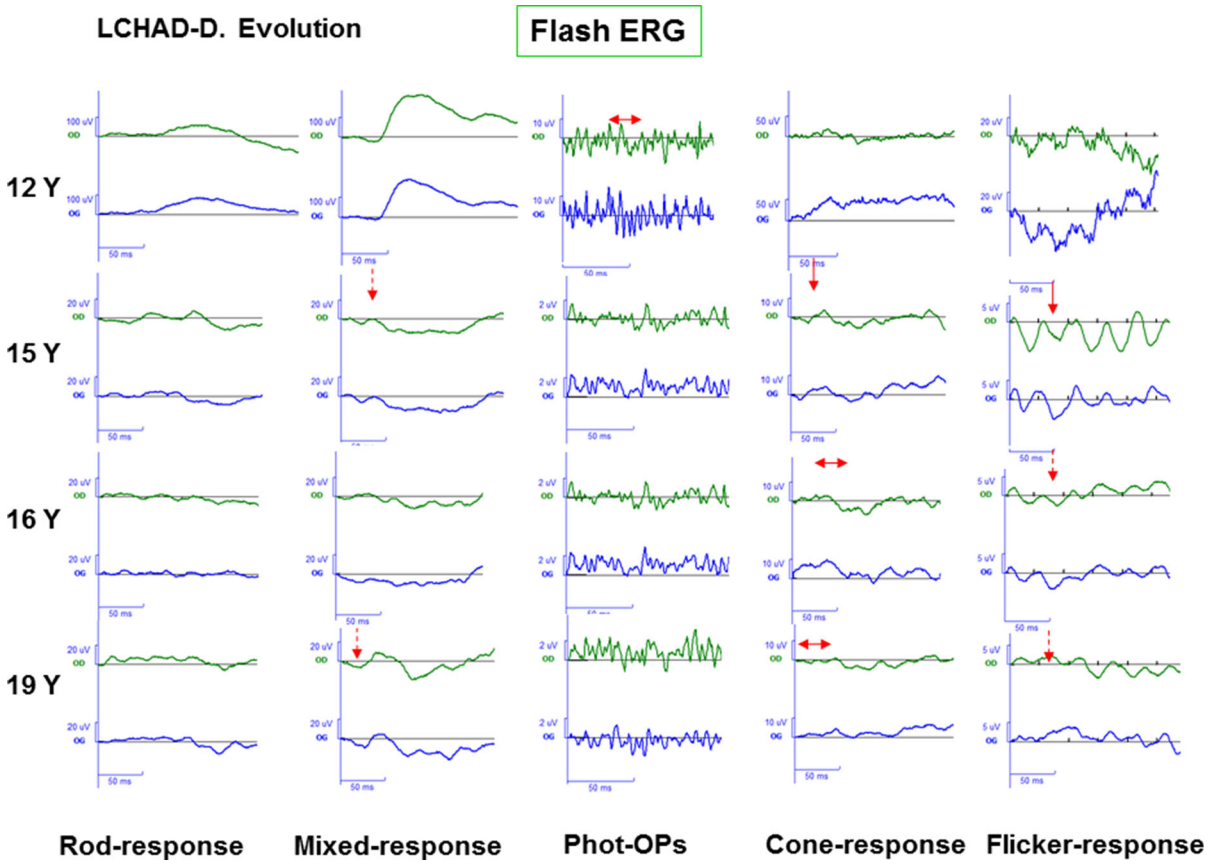

Fig. 6 L. LCHAD-D. Evolution of the standard flash ERG between the age of 12 and 19 years. Amplitude of the scotopic responses was strongly decreased. Right eye: green line Left eye: blue line

scotopic and photopic responses evolved differently. The photopic responses decreased first and slightly from the age of 5 years and continued to decrease with age. The scotopic responses decreased secondly from the age of 12 years on. They then decreased both significantly.

The origin of the LCHAD-D retinopathy has not yet been elucidated [30]. It is probably multifactorial. Gillingham et al. [20] hypothesize that long-chain 3-hydroxyacylcarnitines or related metabolites are toxic for RPE and/or photoreceptor cells, but other factors may be involved. Interestingly, metabolic decompensations and hospitalizations were reported to be associated with progression of retinopathy [24].

In our patient, the dysfunction of the photopic system preceded that of the scotopic one. This dysfunction of cones prior to the dysfunction of rods was not reported previously in other reports of LCHAD-D patients' retinopathy. This notable difference is interesting. We know that cones have higher oxidative activity and energy needs than rods. The aerobic ATP demand of cones is greater in light-adapted situation than that of rods [31, 32]. In LCHAD-D, ATP generation by cones could be severely decreased modifying their visual cycle speed [33]. Therefore, cone apoptosis would be accelerated in comparison with that of rods [31, 32]. This energy deficit may be one of the factors among others at the origin of the photopic retinopathy deficiency preceding that of the scotopic one. This hypothesis needs to be further confirmed and is potentially questionable and insufficient as other long-chain fatty oxidation defective patients (VLCAD and CPT2 deficiencies) do not exhibit retinopathy.

Compliance with ethical standards

Conflict of interest The authors declare that they have no conflict of interest.

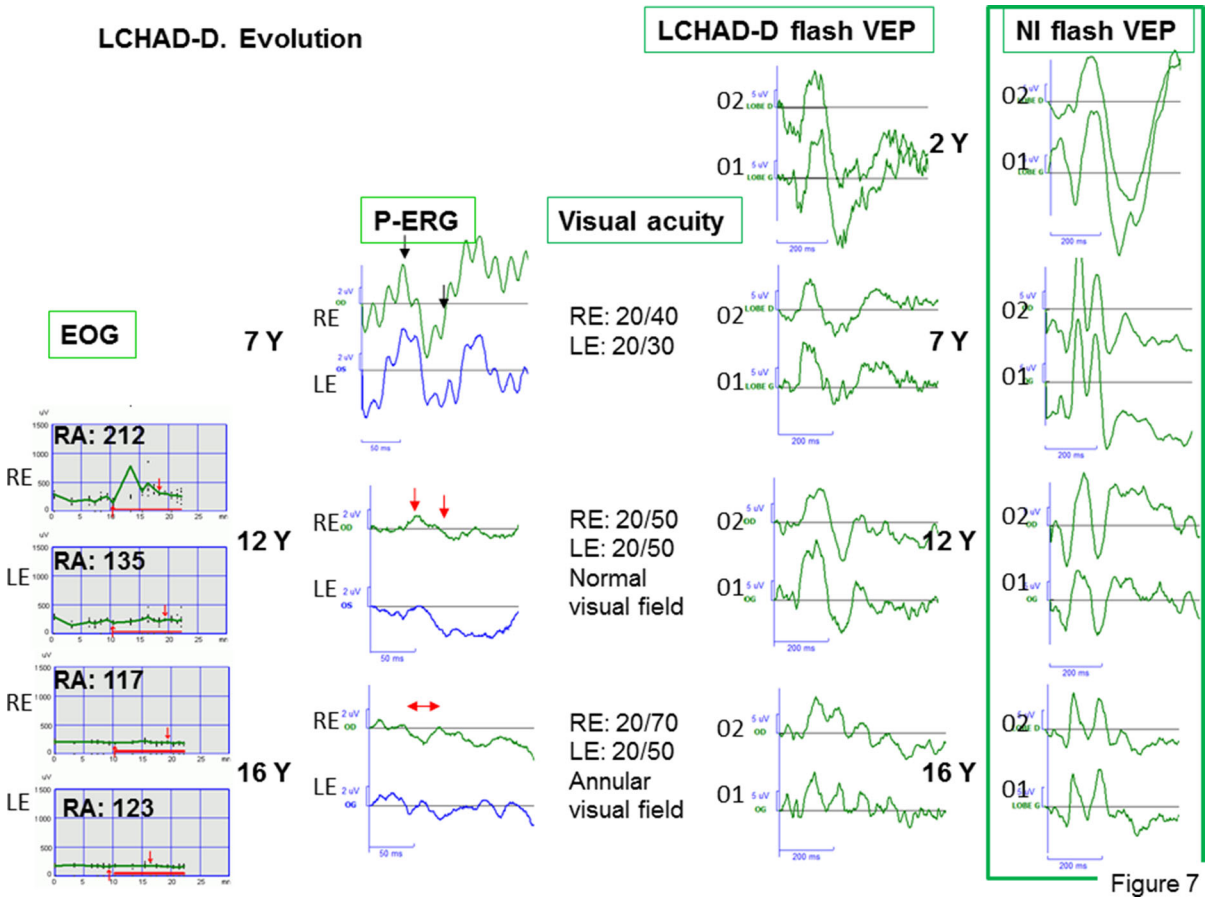

Fig. 7 L. LCHAD-D. Evolution of the standard EOG, P-ERG (Right eye: green line, Left eye: blue line), visual acuity. Flash VEP between the age of 2 and 16 years for the right eye. Upper trace: 02—lower trace: 01. Normal flash VEP on the right at corresponding ages

Informed consent The patient has consented to the submission of the case report for submission to the journal.

Statement of human rights Patient's human rights and her well-being were respected throughout the clinical assessments and electrophysiological recordings over the all assessment period.

Statement on the welfare of animals This article does not contain any studies with animals performed by any of the authors.

References

1. Knottnerus SJG et al (2018) Disorders of mitochondrial long-chain fatty acid oxidation and the carnitine shuttle. Rev Endocr Metab Disord 19(1):93–106
2. Uchida Y et al (1992) Novel fatty acid beta-oxidation enzymes in rat liver mitochondria. II. Purification and properties of enoyl-coenzyme A (CoA) hydratase/3-hydroxyacyl-CoA dehydrogenase/3-ketoacyl-CoA thiolase trifunctional protein. J Biol Chem 267(2):1034–1041
3. IJlst L et al (1996) Common missense mutation G1528C in long-chain 3-hydroxyacyl-CoA dehydrogenase deficiency. Characterization and expression of the mutant protein, mutation analysis on genomic DNA and chromosomal localization of the mitochondrial trifunctional protein alpha subunit gene. J Clin Invest 98(4):1028–1033
4. Roomets E, Kivela T, Tyni T (2008) Carnitine palmitoyltransferase I and Acyl-CoA dehydrogenase 9 in retina: insights of retinopathy in mitochondrial trifunctional protein defects. Invest Ophthalmol Vis Sci 49(4):1660–1664
5. den Boer ME et al (2002) Long-chain 3-hydroxyacyl-CoA dehydrogenase deficiency: clinical presentation and follow-up of 50 patients. Pediatrics 109(1):99–104
6. Fletcher AL et al (2012) Observations regarding retinopathy in mitochondrial trifunctional protein deficiencies. Mol Genet Metab 106(1):18–24
7. Hayes B et al (2007) Long chain fatty acid oxidation defects in children: importance of detection and treatment options. Ir J Med Sci 176(3):189–192

8. Spiekerkoetter U (2010) Mitochondrial fatty acid oxidation disorders: clinical presentation of long-chain fatty acid oxidation defects before and after newborn screening. J Inherit Metab Dis 33(5):527–532
9. Nadjar Y et al (2020) Sensory neuronopathy as a major clinical feature of mitochondrial trifunctional protein deficiency in adults. Rev Neurol (Paris) 176(5):380–386
10. Tyni T et al (1998) Ophthalmologic findings in long-chain 3-hydroxyacyl-CoA dehydrogenase deficiency caused by the G1528C mutation: a new type of hereditary metabolic chorioretinopathy. Ophthalmology 105(5):810–824
11. McCulloch DL et al (2015) ISCEV Standard for full-field clinical electroretinography (2015 update). Doc Ophthalmol 130(1):1–12
12. Bach M et al (2013) ISCEV standard for clinical pattern electroretinography (PERG): 2012 update. Doc Ophthalmol 126(1):1–7
13. Constable PA et al (2017) ISCEV Standard for clinical electro-oculography (2017 update). Doc Ophthalmol 134(1):1–9
14. Odom JV et al (2016) ISCEV standard for clinical visual evoked potentials: (2016 update). Doc Ophthalmol 133(1):1–9
15. Fulton AB, Hartmann EE, Hansen RM (1989) Electrophysiologic testing techniques for children. Doc Ophthalmol 71(4):341–354
16. Bradshaw K, Hansen R, Fulton A (2004) Comparison of ERGs recorded with skin and corneal-contact electrodes in normal children and adults. Doc Ophthalmol 109(1):43–55
17. Acharya JN et al (2016) American clinical neurophysiology society guideline 3: a proposal for standard montages to be used in clinical EEG. J Clin Neurophysiol 33(4):312–316
18. Sturm V (2008) Ophthalmologic abnormalities in long-chain 3-hydroxyacyl-CoA dehydrogenase deficiency: presentation of a long-term survivor. Eur J Ophthalmol 18(3):476–478
19. Jones PM, Butt Y, Bennett MJ (2003) Accumulation of 3-hydroxy-fatty acids in the culture medium of long-chain L-3-hydroxyacyl CoA dehydrogenase (LCHAD) and mitochondrial trifunctional protein-deficient skin fibroblasts: implications for medium chain triglyceride dietary treatment of LCHAD deficiency. Pediatr Res 53(5):783–787
20. Gillingham MB et al (2005) Effect of optimal dietary therapy upon visual function in children with long-chain 3-hydroxyacyl CoA dehydrogenase and trifunctional protein deficiency. Mol Genet Metab 86(1–2):124–133
21. Gillingham M et al (1999) Dietary management of long-chain 3-hydroxyacyl-CoA dehydrogenase deficiency (LCHADD). A case report and survey. J Inherit Metab Dis 22(2):123–131
22. Stopek D et al (2008) Long-chain 3-hydroxyacyl CoA dehydrogenase deficiency and choroidal neovascularization. J Fr Ophtalmol 31(10):993–998
23. Haegerstrom-Portnoy G et al (1996) Clinical vision characteristics of the congenital achromatopsias. I. Visual acuity, refractive error, and binocular status. Optom Vis Sci 73(7):446–456
24. Tyni T, Pihko H, Kivela T (1998) Ophthalmic pathology in long-chain 3-hydroxyacyl-CoA dehydrogenase deficiency caused by the G1528C mutation. Curr Eye Res 17(6):551–559
25. Boese EA et al (2016) Characterization of chorioretinopathy associated with mitochondrial trifunctional protein disorders: long-term follow-up of 21 cases. Ophthalmology 123(10):2183–2195
26. Polinati PP et al (2015) Patient-specific induced pluripotent stem cell-derived RPE cells: understanding the pathogenesis of retinopathy in long-chain 3-hydroxyacyl-CoA dehydrogenase deficiency. Invest Ophthalmol Vis Sci 56(5):3371–3382
27. Ait-Ali N et al (2015) Rod-derived cone viability factor promotes cone survival by stimulating aerobic glycolysis. Cell 161(4):817–832
28. Lawlor DP, Kalina RE (1997) Pigmentary retinopathy in long chain 3-hydroxyacyl-coenzyme A dehydrogenase deficiency. Am J Ophthalmol 123(6):846–848
29. Fahnehjelm KT et al (2008) Ocular characteristics in 10 children with long-chain 3-hydroxyacyl-CoA dehydrogenase deficiency: a cross-sectional study with long-term follow-up. Acta Ophthalmol 86(3):329–337
30. Tyni T et al (2004) Mitochondrial fatty acid beta-oxidation in the human eye and brain: implications for the retinopathy of long-chain 3-hydroxyacyl-CoA dehydrogenase deficiency. Pediatr Res 56(5):744–750
31. Perkins GA, Ellisman MH, Fox DA (2003) Three-dimensional analysis of mouse rod and cone mitochondrial cristae architecture: bioenergetic and functional implications. Mol Vis 9:60–73
32. Wong-Riley MT (2010) Energy metabolism of the visual system. Eye Brain 2:99–116
33. Kolesnikov AV et al (2007) Visual cycle and its metabolic support in gecko photoreceptors. Vis Res 47(3):363–374

Publisher's Note Springer Nature remains neutral with regard to jurisdictional claims in published maps and institutional affiliations.