



# Multifocal electroretinogram in eyes with intravitreal silicone oil and changes following silicone oil removal

Devesh Kumawat · Pranita Sahay · Karthikeyan Mahalingam · S. J. Vikas · Sagnik Sen · Mousumi Banerjee · Pradeep Venkatesh

Received: 6 March 2019 / Accepted: 12 July 2019  
© Springer-Verlag GmbH Germany, part of Springer Nature 2019

## Abstract

**Purpose** To determine the effect of intravitreal silicone oil (SO) on multifocal electroretinogram (mfERG) and the changes in mfERG following SO removal.

**Methods** Twelve eyes of 12 patients with SO in vitreous cavity with corrected distance visual acuity (CDVA) > 20/200 were prospectively enrolled as cases over a period from July 2016 to June 2018. The fellow normal eyes served as control. The eyes were evaluated with P1 and N1 wave amplitude and implicit time on mfERG at baseline, 1 and 4 weeks after SO removal.

**Results** The mean age was  $44.9 \pm 18.9$  (range 18–74) years. The indication for SO injection was retinal detachment ( $n = 9$ , three macula-on eyes, six macula-off eyes) and endophthalmitis ( $n = 3$ ). The median (range) LogMAR CDVA at baseline was 0.54 (0.18–0.78) in cases and did not change post-SO removal ( $p = 0.29$ ). There was a significant decrease

in average P1 and N1 wave amplitude ( $p = 0.0001$  and  $0.0001$ , respectively) and delay in average P1 and N1 wave implicit time ( $p = 0.0002$  and  $0.021$ , respectively) in cases as compared to controls. The macular status and duration of SO tamponade did not have a significant correlation with mfERG parameters. There was a significant increase in average P1 and N1 wave amplitude ( $p = 0.009$  and  $0.003$ , respectively) at 1 week following SO removal but no change in average P1 and N1 wave implicit time ( $p = 0.41$  and  $0.37$ , respectively).

**Conclusion** mfERG may be reliably performed for the assessment of macular function in SO-filled eyes. Intravitreal SO exerts an insulating effect on the density of the electric potentials.

**Keywords** Multifocal electroretinogram · Retinal detachment · Silicone oil · Visual acuity

---

**Electronic supplementary material** The online version of this article (<https://doi.org/10.1007/s10633-019-09710-w>) contains supplementary material, which is available to authorized users.

---

D. Kumawat (✉) · P. Sahay · K. Mahalingam · S. J. Vikas · S. Sen · M. Banerjee · P. Venkatesh  
Dr Rajendra Prasad Centre for Ophthalmic Sciences, All India Institute of Medical Sciences, Room no. 485, Fourth Floor, New Delhi 110029, India  
e-mail: deveshkumawat21@gmail.com

## Introduction

Silicone oil (SO) has been extensively used in the management of vitreoretinal disorders [1]. It has known complications such as secondary glaucoma, corneal decompensation, band-shaped keratopathy, and cataract [2]. With the advent in vitreoretinal surgeries, the use of SO is getting limited to complicated retinal detachments (RD). Unexplained visual loss or functional retinopathy is an uncommon

complication of long-standing intravitreal SO [3–7]. Histological and ultrastructural studies with optical coherence tomography (OCT) have shown degeneration of the inner retinal layers particularly ganglion cell layer with long-term SO endotamponade [5–12]. However, these studies are limited by their cross-sectional analysis and lack of correlation with the electrophysiological parameters.

Full-field electroretinogram (ffERG) has long been performed in SO-filled eyes in animal models and human studies [8, 13–17]. The amplitude of ‘a’ and ‘b’ wave is reduced in SO-filled eyes as compared to the controls. However, the amplitude recovers shortly after silicone oil removal (SOR). Intravitreal SO seems to interfere with the propagation of the electrical impulses. A few studies have evaluated ffERG after SOR in cases with unexplained visual loss following uneventful vitrectomy and SO injection for rhegmatogenous retinal detachment (RRD) [3, 4, 18]. Although these studies report reduced amplitude of ‘a’ and ‘b’ wave as compared to the controls, the results may be confounded by the RD itself. Prospective human studies evaluating the ffERG changes in SO-filled eyes are lacking.

While the ffERG measures the summed electrophysiological activity of the entire retina [19], the multifocal electroretinogram (mfERG) detects local responses from the macula and is sensitive in the detection of various acquired retinal disorders affecting predominantly the macula [20]. There are no studies on the effect of SO on mfERG in the literature. A few studies have evaluated mfERG after SOR in cases of unexplained visual loss following uneventful vitrectomy and found a decreased amplitude of *N1* and *P1* wave of mfERG, which may be consequent to the retinal detachment itself and not due to silicone oil [3, 4]. Also, it is not known whether mfERG may be reliably performed in SO-filled eyes.

This study was performed to determine if mfERG may be reliably obtained in SO-filled eyes, compare the changes in amplitude and latency with normal fellow eyes and see if changes occur after SOR.

## Materials and methods

It was an observational study of patients who underwent SOR after successful vitreoretinal surgery and had mfERG performed before and after removal of

SO, over a period of 2 years (June 2016 to May 2018) at our tertiary eye care center. The study was performed in accordance with the tenets of Declaration of Helsinki. A formal institute ethical committee clearance was obtained for the study.

The inclusion criteria were patients with intravitreal SO in one eye for any vitreoretinal pathology, attached retina with normal macular morphology, an absence of emulsification of SO, adequate fill of SO, corrected visual acuity in both eyes better than 20/200, clear media in both eyes, and lack of vitreoretinal pathology in the fellow eye. The exclusion criteria were the emulsification of SO, under-fill of SO, media opacity such as corneal scarring, nuclear sclerosis, posterior capsular opacification in either eye or presence of primary or secondary glaucoma in either eye. All the cases had 1000 centistokes SO (Aurosil, Aurolab, India) in the vitreous cavity. Patients who underwent additional cataract surgery along with SOR or had redetachment within a month after SOR were excluded from the study. The eyes with SO in situ were taken as cases, and the fellow normal eyes were taken as controls.

The demographic information, ophthalmic history, slit-lamp examination, dilated fundus examination and ocular biometry were recorded. The indication for SO injection and the duration of SO tamponade were noted. The ocular examination details included corrected distance visual acuity (CDVA), intraocular pressure (IOP), the status of the lens (clear crystalline or pseudophakic or aphakic), and the retinal status. Macular spectral-domain OCT was performed to confirm a normal macular morphology (absence of epiretinal membrane/retinal thinning/neurosensory detachment).

The patients underwent mfERG a day prior to SOR and at 1 week and 1 month after SOR. The mfERG was performed on Vision monitor, Monopack 3, Metrovision. The procedure for mfERG was as follows [21]: The eyes were light-adapted for at least 15 min in room light, and pupils were fully dilated with tropicamide 1% eye drop before the test. Refractive correction was provided at the time of test. The corrective lenses were placed in the holder positioned in front of the eye with proper centration. A 61-scaled hexagonal stimulus pattern with central fixation point at a viewing distance of 33 cm (corresponding to a field of  $\pm 30^\circ$  horizontally and  $\pm 24^\circ$  vertically) was used. The luminance of bright hexagon

was maintained at 100 cd/m<sup>2</sup> while that for dark hexagon was < 1 cd/m<sup>2</sup> and for background cover was 30 cd/m<sup>2</sup>. The stimulus frequency was set at 17 Hz. The recording was done using contact lens electrodes (ERG jet<sup>®</sup>, Fabrinal SA) after anesthetizing the cornea with proparacaine 0.5% eye drop.

The standard parameters that were recorded at baseline and follow-up included P1 and N1 wave amplitude and their implicit time. Both the waves were evaluated in five rings in the macular region with ring 1 representing < 2° field, ring 2 representing 2–5° field, ring 3 representing 5–10° field, ring 4 representing 10–15° field and ring 5 representing > 15° field. In each ring, the trace arrays were assessed (Fig. 1). In addition, the visual acuity, retinal status, and macular morphology were also evaluated on follow-up.

The data were entered into an Excel sheet and analyzed using STATA SE 12.1 software. For descriptive purposes, the nonparametric data were expressed as median (range), the parametric qualitative data as a percentage and the quantitative data as mean ± standard deviation (SD). The group averages of P1 and N1 wave amplitude and implicit time were analyzed in each retinal ring and compared between cases and controls as well as in the cases before and

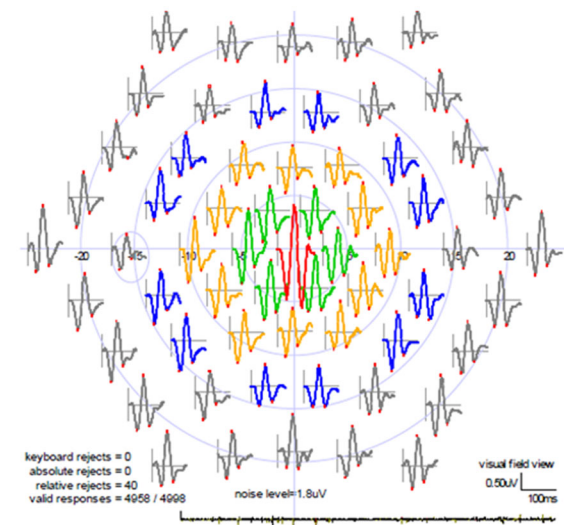
after SOR. The parametric data were compared between the groups with ‘Student *t* test,’ and to see the changes after surgery in cases, ‘Repeated measure analysis’ was used. The nonparametric data were compared between the groups with ‘Mann–Whitney test,’ and to see the changes after surgery in cases, ‘Friedman test’ was used. A *p* value ≤ 0.05 was considered statistically significant.

## Results

Twelve patients (10 males, two females) were included in this study. The mean ± SD (median, range) age was 44.9 ± 18.9 (50, 18–74) years. The indication for SO injection was rhegmatogenous retinal detachment (*n* = 9, three macula-on eyes, six macula-off eyes) and endophthalmitis (*n* = 3). The median duration of detachment in macula-off cases was 45 (range 7–60) days. The SO was injected in RRD cases due to the presence of proliferative vitreoretinopathy or inferior breaks or repeat surgery for failed initial vitrectomy. The median duration of SO tamponade was six (range 3–15) months. The baseline characteristics are presented in Table 1.

The lens status of the cases was as follow: aphakia in four eyes, pseudophakia in seven eyes and clear crystalline lens in one eye. The mean axial length of the cases and controls was 23.3 ± 0.86 mm and 23.1 ± 0.91 mm, respectively (*p* = 0.47). The median spherical equivalent of the cases was 4.375 D (range 1.5–11 D). The baseline central macular thickness in cases was 229.7 ± 20.6 μm.

At baseline, the mean log MAR CDVA in cases and controls was 0.5 ± 0.19 (median 0.54, range 0.18–0.78) and 0.06 ± 0.08 (median 0, range 0–0.18), respectively (*p* = 0.0001). The CDVA at 1-week and 1-month visit post-SOR in cases was 0.47 ± 0.21 (median 0.54, range 0.18–0.78) with no difference as compared to the baseline (*p* = 0.29). The median spherical equivalent of the cases at 4 weeks postoperative follow-up was 1.125 D (range – 1.5–13.5 D).



**Fig. 1** The multifocal electroretinogram (mfERG) of the normal eye of an 18-year-old male patient (case 4). The trace arrays of local responses are shown in the five rings in the macular region with ring 1 representing < 2° field, ring 2 representing 2–5° field, ring 3 representing 5–10° field, ring 4 representing 10–15° field and ring 5 representing > 15° field. The responses are valid, and the noise level is acceptable

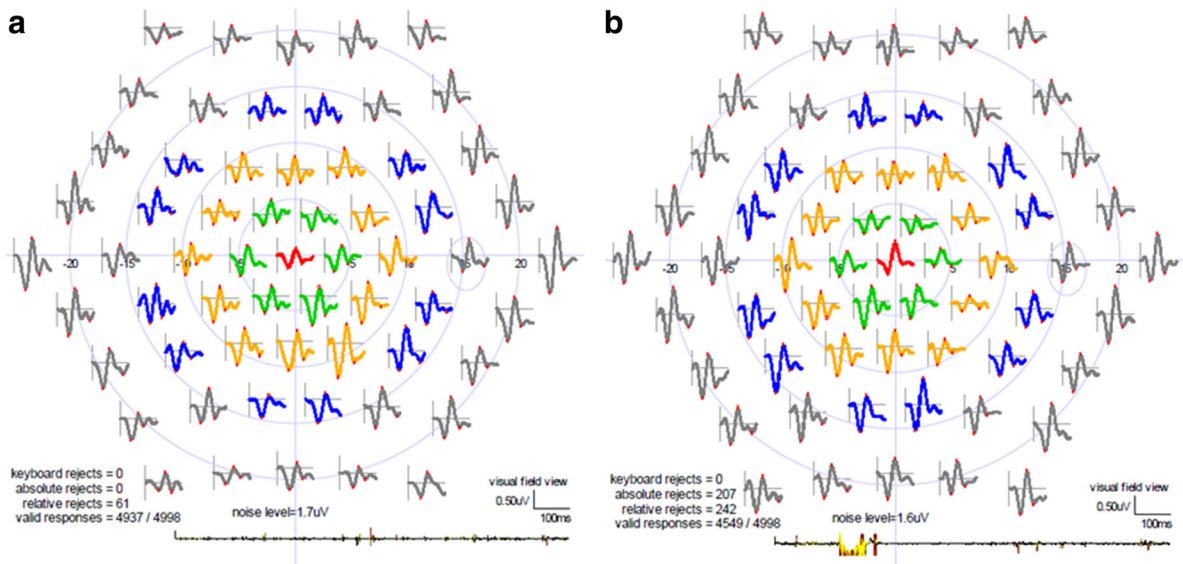
## MfERG

The mfERG trace arrays could be obtained and recognized in all the rings in all cases at baseline as well as on follow-up. The mfERG trace arrays before

**Table 1** Baseline characteristics of cases with silicone oil in the vitreous cavity

Case	Age-years/sex	Indication of silicone oil fill during vitrectomy	Macular status before VR surgery	Duration of detachment (days)	Duration of silicone oil tamponade (months)	Baseline log MAR CDVA	Affected eye lens status	Fellow eye lens status	Spherical equivalent (D)	Affected eye central macular thickness ( $\mu\text{m}$ ) before silicone oil removal
1	48/M	Postcataract surgery	Attached	N/A	6	0.48	Aphakia	Clear	11	234
2	20/M	Failed VR surgery for RRD	Attached	N/A	15	0.18	Pseudophakia	Clear	4	241
3	57/M	RRD with GRT	Detached	45	7	0.6	Pseudophakia	Pseudophakia	1.5	209
4	18/M	Traumatic endophthalmitis	Attached	N/A	4	0.3	Aphakia	Clear	7	221
5	60/M	Postcataract surgery	Attached	N/A	6	0.48	Aphakia	Pseudophakia	8	249
6	61/M	RRD with PVR	Detached	60	5	0.78	Pseudophakia	Pseudophakia	3	223
7	74/M	RRD with PVR	Detached	60	7	0.6	Pseudophakia	Pseudophakia	4.5	199
8	29/M	Failed VR surgery for RRD	Attached	N/A	6	0.78	Aphakia	Clear	5.5	267
9	18/M	Traumatic RRD	Attached	N/A	3	0.3	Clear lens	Clear	7.75	251
10	52/M	RRD with inferior multiple breaks	Detached	7	6	0.3	Pseudophakia	Pseudophakia	4.25	230
11	47/F	RRD with myopic degeneration	Detached	12	3	0.6	Pseudophakia	Pseudophakia	3	232
12	55/F	RRD with inferior multiple breaks	Detached	45	9	0.6	Pseudophakia	Pseudophakia	4.25	201

CDVA corrected distance visual acuity; VR vitreoretinal; RRD rhegmatogenous retinal detachment; GRT giant retinal tear; PVR proliferative vitreoretinopathy; N/A not applicable



**Fig. 2** The multifocal electroretinogram (mfERG) of the affected eye in case 4, who had undergone vitreoretinal surgery and silicone oil tamponade for posttraumatic endophthalmitis. **a** Before silicone oil removal, the trace arrays show depressed

and after SOR of two representative cases (case 4 and case 10) are being shown in Figs. 2 and 3, respectively.

#### P1 wave

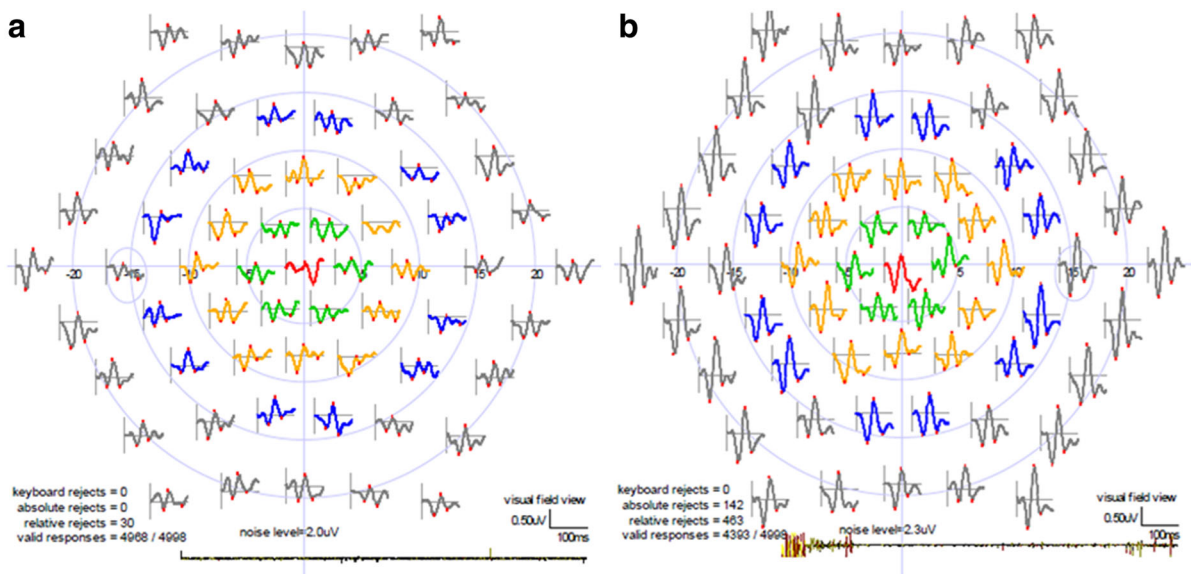
Considering the average of all the retinal rings, the baseline amplitude and implicit time in cases were  $321.4 \pm 116.3$  nV (median 348.1, range 155.6–483.2 nV) and  $52.2 \pm 2.9$  ms, respectively, and that in the control eyes were  $919.9 \pm 259.5$  (median 920.6, range 571.0–1325.0) nV and  $47.1 \pm 2.6$  ms, respectively. The decrease in amplitude and delay in implicit time in cases was statistically different from the controls at baseline ( $p = 0.0001$  and  $0.0002$ , respectively). At 1 week post-SOR, the amplitude in cases improved significantly from baseline to  $531.2 \pm 267.5$  nV (median 409.5, range 254.0–1028.8 nV) ( $p = 0.009$ ). The average amplitude improved by 65% from baseline at 1 week. There was no further change noted in the average amplitude at 4-week follow-up ( $504.9 \pm 266.8$  nV [median 412.3, range 254.8–1124.2]) ( $p = 0.30$ ). However, the implicit time in cases did not improve significantly on follow-up

peaks of the responses in all the rings. **b** Four weeks postsilicone oil removal, the trace array waveforms have improved in the amplitude. The responses are valid, and the noise level is acceptable at both the visits

( $51.4 \pm 2.9$  ms at 1 week and  $50.8 \pm 1.7$  ms at 4 weeks) ( $p = 0.41$ ).

#### N1 wave

Considering the average of all the retinal rings, the baseline amplitude and implicit time in cases were  $-207.3 \pm 31.6$  nV (median  $-210.7$ , range  $-156.7$  to  $-273.1$  nV) and  $31.7 \pm 2.1$  ms, respectively, and that in the control eyes were  $-433.9 \pm 122.8$  nV (median  $-407.0$ , range  $-282.6$  to  $-716.4$  nV) and  $29.2 \pm 2.7$  ms, respectively. The decrease in amplitude (absolute values) and delay in implicit time in cases were statistically different from the controls at baseline ( $p = 0.0001$  and  $0.021$ , respectively). At 1 week post-SOR, the amplitude in cases improved (absolute value) significantly from baseline to  $-329.9 \pm 116.1$  nV (median  $-299.5$ , range  $-194.4$  to  $-599.2$  nV) ( $p = 0.003$ ). The average amplitude improved by 59% from baseline at 1 week. There was no further change noted at 4-week follow-up ( $-336.8 \pm 137.9$  nV [median  $-274.6$  range  $-179.0$  to  $-666.6$  nV]) ( $p = 0.58$ ). However, the implicit time in cases did not improve significantly on follow-up ( $32.8 \pm 2.3$  ms at 1 week and  $31.9 \pm 2.2$  ms at 4 weeks) ( $p = 0.37$ ).



**Fig. 3** The multifocal electroretinogram (mfERG) of the affected eye in case 10, who had undergone vitreoretinal surgery and silicone oil tamponade for macula-off rhegmatogenous retinal detachment with multiple inferior breaks. **a** Before silicone oil removal, the trace arrays show depressed peaks of

the responses in all the rings. The waveform shapes are not as good as seen in case 4 in Fig. 2. **b** Four weeks postsilicone oil removal, the trace array waveforms have improved in the shape as well as the amplitude. The responses are valid and the noise level is acceptable at both the visits

The baseline mfERG parameters did not have a significant correlation with baseline CDVA in both the cases and controls and the duration of macular detachment and duration of SO tamponade in the cases (see Online Resource ESM\_1, which shows the Spearman correlation of baseline parameters with mfERG variables).

The macula-on cases ( $n = 6$ ) and macula-off cases ( $n = 6$ ) were compared regarding the average  $P1$  and  $N1$  wave amplitude and implicit time at baseline and on follow-up (see Online Resource ESM\_2, which shows the comparison of mfERG variables between macula-on and macula-off eyes). The baseline amplitude and implicit time were comparable for  $P1$  wave ( $p = 0.33$  and  $0.99$ , respectively) and  $N1$  wave ( $p = 0.14$  and  $0.63$ , respectively). However, at 1-week follow-up, the amplitude of  $P1$  and  $N1$  wave was significantly greater in macula-on cases as compared to macula-off cases ( $p = 0.037$  and  $0.003$ , respectively). At 4-week follow-up, this difference in  $P1$  and  $N1$  wave amplitude between the macula-on and macula-off cases was maintained ( $p = 0.003$  and  $0.010$ , respectively).

## Discussion

In the recent years, silicone oil-related visual loss (SORVL) has been reported during SO tamponade after uncomplicated vitrectomy or shortly following SOR, wherein there occurs unexplained profound visual loss in the absence of clinically visible retinal changes [3–7]. SORVL occurs in up to 30% of eyes with macula-on RRD [7]. However, the majority of eyes do not have clinical SO retinopathy and the pathophysiological mechanisms of this phenomenon are not clear [9].

Electrophysiology has long been evaluated in SO-filled eyes in animal models [8, 17]. However, the limiting factor is the effect of silicone oil itself on the measurement of the variables. Assessment may be difficult to perform and interpret in SO-filled eyes. A few animal studies have reported early and lasting reduction in ‘b’ wave amplitudes of ffERG after vitrectomy and SO injection [8], while others report no significant decline in ffERG responses in the first several weeks after SO injection into vitrectomized animal eyes [13]. Human studies are also limited to the evaluation of ffERG after long-term tamponade in vitreoretinal surgeries [14–17]. The ffERG responses

in such eyes are markedly diminished as compared to the controls. Some believe it to be due to an insulating effect of the SO, while others think it to be due to retinal dysfunction.

The insulating effect of SO can be best understood with studies evaluating the electrophysiology just before and after SOR. It has been observed that the ffERG response increase significantly after SOR and this puts a question on the possible functional retinopathy [14–16]. The ffERG measures the mass potential of the entire retina and may not be representative of the macular changes [19]. MfERG overcomes this shortcoming of ffERG as it gives a topographic measure of the electrophysiological activity at the macula [22]. MfERG gets affected early in the course of various acquired retinal disorders affecting predominantly the macula and therefore is more sensitive than ffERG in these disorders [20]. However, the cellular contributions to the human mfERG are not very well understood [22, 23].

The present study shows that reliable mfERG trace arrays could be obtained in the presence of intravitreal silicone oil. It also demonstrates how the presence of SO in the vitreous cavity affects the measurement of mfERG parameters. At baseline, there was a significant decrease in amplitude and delay in implicit time of mfERG in SO-filled eyes as compared to the normal fellow eyes. The results are similar to the ffERG changes reported in the literature [16, 17]. The reduced amplitude and prolonged implicit time may result from the RD/endophthalmitis or vitrectomy itself and not per se due to silicone oil alone.

The amplitude of *M1* and *P1* waves improved shortly after SOR and remained stable after that. The second postoperative visit (at 4 weeks) was chosen to remove any short-term electrophysiological fluctuations immediately following SOR. The implicit time did not change significantly after SOR. Intravitreal SO appears to have an insulating effect on the propagation of electric potentials. It may interfere with the measurement of the density of electrical potentials generated from the retina. But, it may not affect the synaptic transmission within the retina and therefore the implicit time is not changed.

Striking results were noted regarding the correlation of the macular status with the mfERG parameters. We believe that the intravitreal SO may have a differential interference with the propagation of electric potentials from different layers of the retina. The

contribution to the density of electrical potentials from the outer retinal layers at the macula may be interfered more by the intravitreal SO. It may be due to this reason that the macular-on and macula-off cases did not differ in terms of *M1* and *P1* amplitude and latency at baseline, but macula-on cases had greater amplitudes after SOR. However, this is just a hypothesis and needs to be studied at length.

The duration of SO tamponade did not have a significant correlation with any mfERG parameter in our study. Similarly, Lee et al. [9] did an ultrastructural study with OCT and found that the SO tamponade duration did not have a significant correlation with the degree of retinal thinning. However, Lou et al. [24] had previously reported that the duration of SO endotamponade has a significant effect on the retinal saturation measured with oximetry. Intravitreal SO for more than 9 months was found to alter the retinal saturation and cause narrowing of the retinal arterioles. Perhaps the duration of tamponade was much less in our study (median 6 months) and the study by Lee et al. (mean 101 days). Histological studies have also shown retinal changes to appear only after 6 months to 1 year after SO tamponade [12, 25].

The present study carries useful practical implications. Since the implicit time did not vary with the presence of intravitreal SO, it may reliably be used as a marker of retinal function in SO-filled eyes. MfERG can be performed prospectively in eyes with intravitreal SO to see if any electrophysiological changes occur with increasing duration of the tamponade. Although we did not have eyes with SORVL in our study, mfERG may provide better insights into the occurrence of this phenomenon. This will improve our understanding regarding the questionable maculopathy in these eyes. However, certain precautions need to be taken while performing mfERG. The investigation needs to be performed as per the standard guidelines [21]. Factors such as pupil diameter and media opacities affect the stimulus luminance and can influence the amplitude of electrical activity but not the implicit time [21].

The study had important limitations. Multiple variables could have confounded the electrophysiological function such as the indication for surgery (retinal detachment or endophthalmitis), duration of macular detachment, duration of SO endotamponade, amount of SO fill, difference in refractive correction and retinal illumination before and after SOR and its

effect on mfERG, duration from vitrectomy to mfERG and from SOR to repeat mfERG. As the amount of SO fill increases, the ERG amplitudes become smaller as shown by Doslak in a model-based study [26]. Since we excluded the cases with under-fill of SO and the axial length in affected eyes was nearly similar (mean 23.3 mm with a small SD of 0.86 mm), the fill may have been same in our study. Full refractive correction is usually required to negate the effect of optical blur on mfERG [21]. But, when high, the refractive error from intravitreal SO may affect the image size and hence the mfERG results [21]. The retinal illumination is also different (usually higher for high energy blue light) in eyes with intravitreal SO [27]. However, there seems to be no alternative way while comparing data before and after silicone oil removal to avoid these factors. Another important limitation was that the mfERG changes were not correlated with the ultra-structural changes on OCT.

To conclude, this study lays the foundation for future prospective electrophysiological projects in SO-filled eyes that may provide better insight into the possible physiological dysfunction occurring in these eyes.

#### Compliance with ethical standards

**Conflict of interest** The authors declare that they have no conflict of interest.

**Informed consent** Informed consent was obtained from all individual participants included in the study.

**Statement of human rights** All procedures performed in studies involving human participants were in accordance with the ethical standards of the institutional research committee (All India Institute of Medical Sciences, New Delhi, India; reference number- IECPG-484) and with the 1964 Helsinki Declaration and its later amendments or comparable ethical standards.

**Statement on the welfare of animals** This article does not contain any studies with animals performed by any of the authors.

#### References

- Barca F, Caporossi T, Rizzo S (2014) Silicone oil: different physical proprieties and clinical applications. *BioMed Res Int* 2014:502143. <https://doi.org/10.1155/2014/502143>
- Miller JB, Papakostas TD, Vavvas DG (2014) Complications of emulsified silicone oil after retinal detachment repair. *Semin Ophthalmol* 29:312–318. <https://doi.org/10.3109/08820538.2014.962181>
- Newsom RSB, Johnston R, Sullivan PM et al (2004) Sudden visual loss after removal of silicone oil. *Retina Phila Pa* 24:871–877
- Cazabon S, Groenewald C, Pearce IA, Wong D (2005) Visual loss following removal of intraocular silicone oil. *Br J Ophthalmol* 89:799–802. <https://doi.org/10.1136/bjo.2004.053561>
- Scheerlinck LM, Schellekens PA, Liem AT et al (2016) Incidence, risk factors, and clinical characteristics of unexplained visual loss after intraocular silicone oil for macula-on retinal detachment. *Retina Phila Pa* 36:342–350. <https://doi.org/10.1097/IAE.0000000000000711>
- Scheerlinck LM, Schellekens PA, Liem AT et al (2018) Retinal sensitivity following intraocular silicone oil and gas tamponade for rhegmatogenous retinal detachment. *Acta Ophthalmol (Copenh)* 96:641–647. <https://doi.org/10.1111/aos.13685>
- Christensen UC, la Cour M (2012) Visual loss after use of intraocular silicone oil associated with thinning of inner retinal layers. *Acta Ophthalmol (Copenh)* 90:733–737. <https://doi.org/10.1111/j.1755-3768.2011.02248.x>
- Mukai N, Lee PF, Oguri M, Schepens CL (1975) A long-term evaluation of silicone retinopathy in monkeys. *Can J Ophthalmol* 10:391–402
- Lee SH, Han JW, Byeon SH et al (2018) Retinal layer Segmentation After Silicone Oil Or Gas Tamponade For Macula-On Retinal Detachment Using Optical Coherence Tomography. *Retina Phila Pa* 38:310–319. <https://doi.org/10.1097/IAE.0000000000001533>
- Caramoy A, Droegge KM, Kirchhof B, Fauser S (2014) Retinal layers measurements in healthy eyes and in eyes receiving silicone oil-based endotamponade. *Acta Ophthalmol (Copenh)* 92:e292–e297. <https://doi.org/10.1111/aos.12307>
- Purtskhvanidze K, Hillenkamp J, Tode J et al (2017) Thinning of inner retinal layers after vitrectomy with silicone oil versus gas endotamponade in eyes with macula-off retinal detachment. *Ophthalmol J Int Ophthalmol Int J Ophthalmol Z Augenheilkd* 238:124–132. <https://doi.org/10.1159/000477743>
- Ni C, Wang WJ, Albert DM, Schepens CL (1983) Intravitreal silicone injection. Histopathologic findings in a human eye after 12 years. *Arch Ophthalmol Chic III* 1960 101:1399–1401
- Meredith TA, Lindsey DT, Edelhauser HF, Goldman AI (1985) Electroretinographic studies following vitrectomy and intraocular silicone oil injection. *Br J Ophthalmol* 69:254–260
- Azarmina M, Soheilian M, Azarmina H, Hosseini B (2011) Electroretinogram changes following silicone oil removal. *J Ophthalmic Vis Res* 6:109–113
- Thaler A, Lessel MR, Gnad H, Heilig P (1986) The influence of intravitreally injected silicone oil on electrophysiological potentials of the eye. *Doc Ophthalmol Adv Ophthalmol* 62:41–46
- Foerster MH, Esser J, Laqua H (1985) Silicone oil and its influence on electrophysiologic findings. *Am J Ophthalmol* 99:201–206



17. Momirov D, van Lith GH, Zivojnović R (1983) Electroretinogram and electrooculogram of eyes with intravitreally injected silicone oil. *Ophthalmol J Int Ophthalmol Int J Ophthalmol Z Augenheilkd* 186:183–188. <https://doi.org/10.1159/000309284>
18. Moya R, Chandra A, Banerjee PJ et al (2015) The incidence of unexplained visual loss following removal of silicone oil. *Eye* 29:1477–1482. <https://doi.org/10.1038/eye.2015.135>
19. Scholl HP, Zrenner E (2000) Electrophysiology in the investigation of acquired retinal disorders. *Surv Ophthalmol* 45:29–47
20. Lai TYY, Chan W-M, Lai RYK et al (2007) The clinical applications of multifocal electroretinography: a systematic review. *Surv Ophthalmol* 52:61–96. <https://doi.org/10.1016/j.survophthal.2006.10.005>
21. Hood DC, Bach M, Brigell M et al (2012) ISCEV standard for clinical multifocal electroretinography (mfERG) (2011 edition). *Doc Ophthalmol Adv Ophthalmol* 124:1–13. <https://doi.org/10.1007/s10633-011-9296-8>
22. Hood DC, Frishman LJ, Saszik S, Viswanathan S (2002) Retinal origins of the primate multifocal ERG: implications for the human response. *Investig Ophthalmol Vis Sci* 43:1673–1685
23. Hood DC, Bach M, Brigell M et al (2008) ISCEV guidelines for clinical multifocal electroretinography (2007 edition). *Doc Ophthalmol Adv Ophthalmol* 116:1–11. <https://doi.org/10.1007/s10633-007-9089-2>
24. Lou B, Yuan Z, He L et al (2015) The changes of retinal saturation after long-term tamponade with silicone oil. *BioMed Res Int*. <https://doi.org/10.1155/2015/713828>
25. Gonvers M, Hornung JP, de Courten C (1986) The effect of liquid silicone on the rabbit retina. Histologic and ultrastructural study. *Arch Ophthalmol Chic III* 1960 104:1057–1062
26. Doslak MJ (1989) Quantitative analysis of the insulating effect of silicone oil on the electroretinogram. *Med Biol Eng Comput* 27:254–259
27. Dogramaci M, Williams K, Lee E, Williamson TH (2013) Foveal light exposure is increased at the time of removal of silicone oil with the potential for phototoxicity. *Graefes Arch Clin Exp Ophthalmol Albrecht Von Graefes Arch Klin Exp Ophthalmol* 251:35–39. <https://doi.org/10.1007/s00417-012-2033-5>

**Publisher's Note** Springer Nature remains neutral with regard to jurisdictional claims in published maps and institutional affiliations.