

## Posterior polar annular and hemispheric choroidal and retinal dystrophy: Optical coherence tomographic angiography description of a rare case

Raja Narayanan

Posterior polar annual choroidal dystrophy is a rare disease which affects the retina and choroid in an annular pattern. Our patient was referred to us a case of atypical retinitis pigmentosa. Fundus examination showed a normal optic disc, normal arterioles, and no bone spicules. The right eye showed a hemispheric pattern and the left eye showed an annular pattern of retinal and choroidal dystrophy. We describe the retinal and choroidal angiographic features of this case by optical coherence angiography.

**Key words:** Dystrophy, optical coherence tomographic angiography, posterior polar annular choroidal dystrophy

Posterior polar annular choroidal dystrophy (PPACD) and posterior polar hemispherical choroidal dystrophy are rare entities and have been described only recently.<sup>[1-3]</sup> This disease typically spares the fovea, and there is no arteriolar attenuation or bone spicule formation. However, the rod and cone response of electroretinography (ERG) has been described to be affected in these patients. This case illustrates the occurrence of posterior annular and hemispheric dystrophy in the same patient, which

may be a part of the same spectrum of disease. This case also describes optical coherence tomographic angiography (OCTA) features in this disease.

### Case Report

A 48-year-old gentleman presented to us with complaints of painless diminution of vision, especially in dim light since the past 4 months. He was elsewhere diagnosed to have retinitis pigmentosa. He was diagnosed with hypertension 4 months ago. His best-corrected visual acuity was 20/20, N6 in both eyes. His intraocular pressure was 20 mm Hg in both eyes. Anterior segment was within normal limits. Fundus examination of both eyes showed normal optic disc, no arteriolar narrowing, and no bone spicules. The posterior pole of the right eye showed a hemispheric area of retinal pigment epithelium (RPE) and choriocapillaris atrophy around the inferior arcade, whereas the left eye showed an annular area of the same features at the posterior pole [Fig. 1a and b]. The area of atrophy extended nasal to the disc in both the eyes. Autofluorescence (Optos, Marlborough, MA, USA) showed an area of severe reduction in signals corresponding to the area of atrophy [Fig. 1c and d]. ERG (Metrovision, Pérenchies, France) showed mild reduction in scotopic and photopic a- and b-waves and significant reduction in 30-Hz flicker response and oscillatory potentials [Fig. 2]. Swept source OCT (Triton, Topcon, Tokyo, Japan) of the fovea and subfoveal choroid was essentially normal. However, there was thinning of the retina with lack of architecture of the retinal layers in the areas of annular RPE and choriocapillaris atrophy [Fig. 3a and b]. There was associated significant reduction in choroidal thickness in the area of atrophy, with absence of Sattler layer, and the choroidal vascularity was reduced. OCTA showed normal retinal vasculature at the fovea and subfoveal choroid. However, the deep capillary plexus of the retina was significantly reduced, along with the absence of choriocapillary plexus in the affected atrophic areas [Fig. 4].

Access this article online	
Quick Response Code:	Website: <a href="http://www.ijo.in">www.ijo.in</a>
	DOI: 10.4103/ijo.IJO_367_18

Smt. Kanuri Santhamma Center for Vitreoretinal Diseases, L V Prasad Eye Institute, Hyderabad, Telangana, India

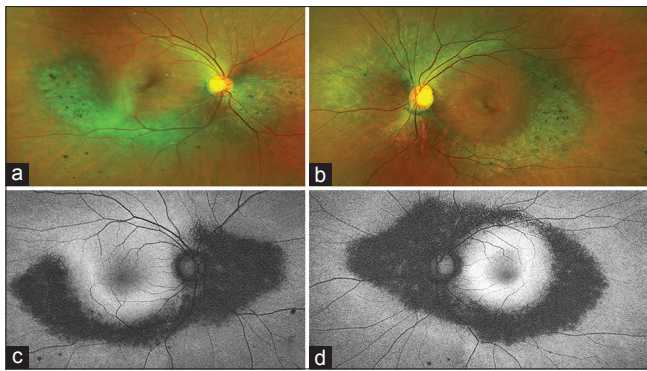
**Correspondence to:** Dr. Raja Narayanan, L V Prasad Eye Institute, Hyderabad - 500 034, Telangana, India. E-mail: [narayanan@lvpei.org](mailto:narayanan@lvpei.org)

**Manuscript received:** 30.03.18; **Revision accepted:** 29.06.18

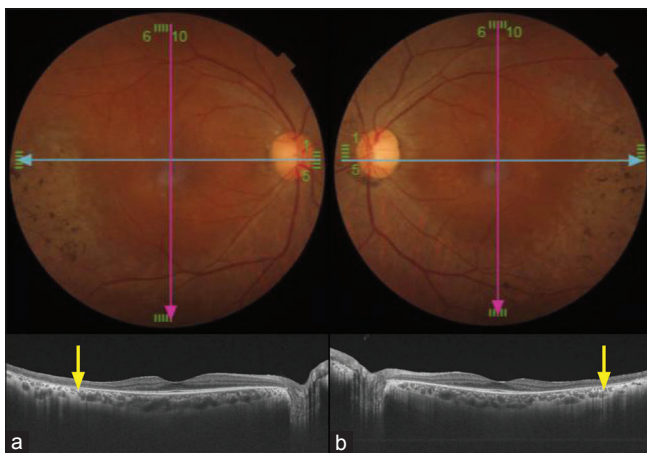
This is an open access journal, and articles are distributed under the terms of the Creative Commons Attribution-NonCommercial-ShareAlike 4.0 License, which allows others to remix, tweak, and build upon the work non-commercially, as long as appropriate credit is given and the new creations are licensed under the identical terms.

**For reprints contact:** [reprints@medknow.com](mailto:reprints@medknow.com)

**Cite this article as:** Narayanan R. Posterior polar annular and hemispheric choroidal and retinal dystrophy: Optical coherence tomographic angiography description of a rare case. *Indian J Ophthalmol* 2018;66:1874-6.



**Figure 1:** The posterior pole of the right eye showed a hemispheric area of retinal pigment epithelium and choriocapillaris atrophy around the inferior arcade, whereas the left eye showed an annular area of the same features at the posterior pole (a and b). The area of atrophy extended nasal to the disc in both the eyes. Autofluorescence showed an area of severe reduction in signals corresponding to the area of atrophy (c and d)

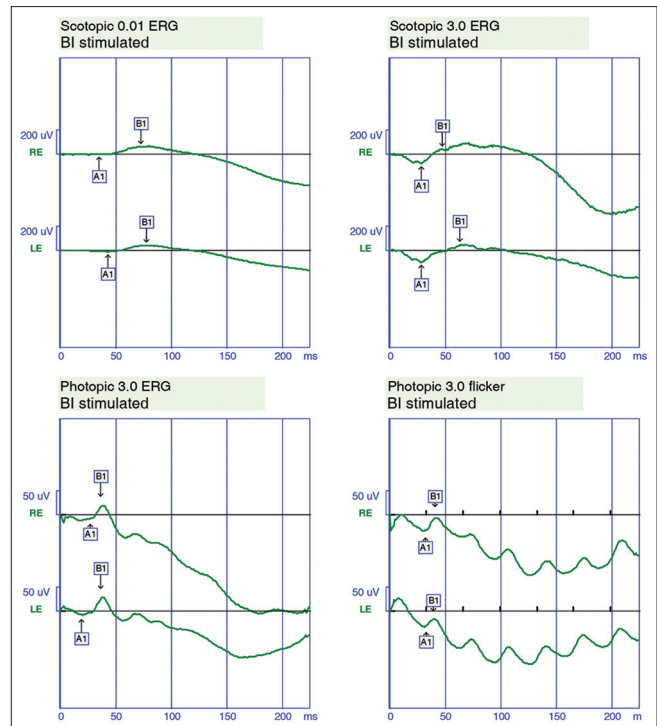


**Figure 3:** Swept source optical coherence tomographic of the fovea and subfoveal choroid was essentially normal. However, there was thinning of the retina with lack of architecture of the retinal layers in the areas of annular retinal pigment epithelium and choriocapillaris atrophy. There was associated significant reduction in choroidal thickness in the area of atrophy, with absence of Sattler layer, and the choroidal vascularity was reduced beyond the normal fovea (arrows)

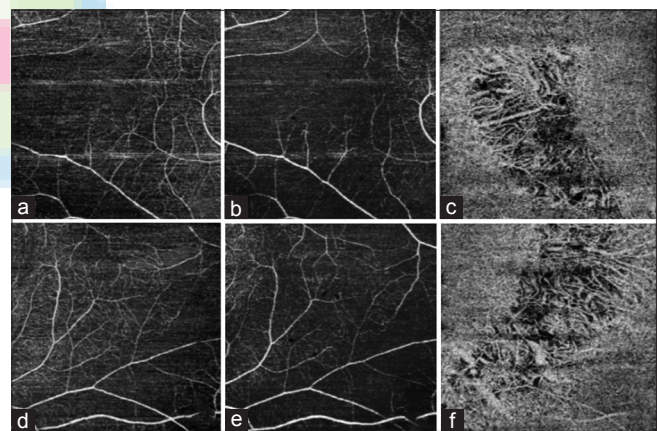
The choroidal vascularity was reduced in the deeper choroid only in the affected areas. Humphrey visual field test showed superior arcuate scotoma in the right and annular scotoma in the left eye.

### Discussion

The first case of PPACD was described by Yannuzzi. Recently, a few other cases of PPACD and hemispheric dystrophy have been described. However, in all the cases, both eyes had either annular or hemispheric choroidal dystrophy. Our patient had annular dystrophy in one eye and hemispheric dystrophy in the other. This suggests that annular and hemispheric dystrophy should be considered as a single entity. Since long-term follow-up is not available in most cases, it is quite possible that hemispheric dystrophy may progress to annular dystrophy. Hence, both annular and hemispheric choroidal dystrophy should be termed as PPACD. Fluorescein



**Figure 2:** Electroretinography of both eyes showed mild reduction in scotopic and photopic a- and b-waves and significant reduction in 30-Hz flicker response



**Figure 4:** The superficial capillary plexus of both eyes (a and d) was normal. The deep capillary plexus of the retina was significantly reduced in the right and left eyes, respectively (b and e), along with the absence of choriocapillary plexus in the affected atrophic areas of right and left eyes (c and f). The choroidal vascularity was reduced in the deeper choroid only in the affected areas

angiography has been described to have window defects.<sup>[2]</sup> However, Fluorescein angiography (FA) cannot segment the vasculature of the retina and choroid, unlike OCTA. OCTA has the ability to show vascularity in different layers of the retina and choroid, which helps in localizing the pathology. OCTA in our case showed reduction in retinal vasculature in deep capillary plexus, as well as loss of choriocapillaris in the affected area. The superficial retinal capillary plexus was largely unaffected. The associated retinal thinning and reduction in retinal vasculature suggests that this may be a form

of chorioretinal dystrophy. The unaffected fovea had normal retinal and choroidal vasculature. In the area of choroidal thinning, OCT showed loss of inner retinal architecture and retinal thinning. ERG showed a reduction in a- and b-waves, as well as loss of oscillatory potentials and 30 Hz flicker response. The reduction in a-waves on flash ERG suggests that there may be a diffuse functional dysfunction of the photoreceptors in this disease, and not just localized to the area of atrophy. However, anatomically, the area of dystrophy appears to be limited in a hemispheric or annular pattern at the posterior pole. Long-term follow-up may help understand whether the areas of atrophy expand over time.

## Conclusion

PPACD may be a chorioretinal dystrophy, with hemispheric and annular dystrophy as part of the same spectrum of disease.

## Declaration of patient consent

The authors certify that they have obtained all appropriate patient consent forms. In the form the patient(s) has/have given his/her/their consent for his/her/their images and other

clinical information to be reported in the journal. The patients understand that their names and initials will not be published and due efforts will be made to conceal their identity, but anonymity cannot be guaranteed.

## Financial support and sponsorship

Nil.

## Conflicts of interest

There are no conflicts of interest.

## References

1. Yannuzzi LA, editor. Posterior polar hemispheric choroidal dystrophy. In: *The Retina Atlas*. Philadelphia: Saunders; 2010. p. 85.
2. Lenis TL, Klufas MA, Randhawa S, Sharma M, Sarraf D. Posterior polar annular choroidal dystrophy: A case series. *Retin Cases Brief Rep* 2017;11 Suppl 1:S24-7.
3. Forte R, Aptel F, Feldmann A, Chiquet C. Multimodal Imaging of posterior polar annular choroidal dystrophy. *Retin Cases Brief Rep* 2018;12:29-32.