

See discussions, stats, and author profiles for this publication at: <https://www.researchgate.net/publication/266626642>

Reliability of Intravitreal Nepafenac in Rabbits

Article in *Journal of Ocular Pharmacology and Therapeutics* · October 2014

DOI: 10.1089/jop.2014.0053 · Source: PubMed

CITATIONS

5

READS

70

8 authors, including:



Filiz Afrashi
Ege University

49 PUBLICATIONS 302 CITATIONS

[SEE PROFILE](#)



Arzu Seyhan Karatepe Hashas
Kayseri Education and Research Hospital

27 PUBLICATIONS 43 CITATIONS

[SEE PROFILE](#)



Mesut Arici
Ege University

18 PUBLICATIONS 152 CITATIONS

[SEE PROFILE](#)



Mehmet Salih Yıkılmaz
Ege University

14 PUBLICATIONS 9 CITATIONS

[SEE PROFILE](#)

Some of the authors of this publication are also working on these related projects:



Computational Glycomics approach to Glypican-I and Prion interactions [View project](#)



Status of Pyrethroid Resistance in *Culex pipiens* in Northern Izmir [View project](#)

Reliability of Intravitreal Nepafenac in Rabbits

Filiz Afrashi,¹ Arzu Seyhan Karatepe Hashas,² Cahit Shahbazov,³ Mesut Arici,⁴ Mehmet Salih Yikilmaz,⁵ Remziye Devenci,⁵ Sabire Karacali,⁵ and Umut Sahar⁵

Abstract

Purpose: The purpose of this experiment was to investigate the possible toxic effects of Nepafenac, a non-steroidal anti-inflammatory molecule, after its intravitreal application in various concentrations.

Methods: Forty pigmented rabbits were randomly divided into 4 groups, each including 10 rabbits. The active ingredient Nepafenac was prepared to be applied in different doses, for intravitreal use. Under topical anesthesia, following pupil dilatation, 0.3, 0.5, 0.75, and 1.5 mg doses of Nepafenac was applied intravitreally into the right eye. In each rabbit, the right eye was considered to be the study group. Saline was injected intravitreally into the left eye of each rabbit, and these eyes were considered to be the control group. Immediately after the injection and at the 1st, 4th, and 8th weeks, fundus examination by indirect ophthalmoscopy and intraocular pressure measurement were conducted. Furthermore, electroretinographic (ERG) recordings were taken at the 4th and 8th weeks. At the end of the 8th week, eyes of the surviving 26 rabbits were enucleated, and then animals were sacrificed. Following necessary fixation procedures, histopathological investigations were conducted by using a light and electron microscope. In the histological cross sections, differences between the eyes with injection and the control group were evaluated, and total retinal thickness, inner nuclear layer thickness, and outer nuclear layer thickness were measured.

Results: No pathology was found by clinical examination of either group. In the photopic and scotopic full-field ERG, conducted before the injection and in the 4th and 8th weeks after the injection, no statistically significant difference was determined between the study group and the control group. In the histological evaluation of the preparations, there were no statistically significant differences in the retina thickness of control and study groups. In the electron microscopic examinations, there were no toxicity findings in the eyes with injection.

Conclusions: Our data show that intravitreal application of 0.3, 0.5, 0.75, and 1.5 mg doses of Nepafenac active substance is nontoxic to the rabbit retina.

Introduction

AS IS THE CASE IN ALL INFLAMMATIONS, prostaglandin production increases where ocular inflammation is triggered. In the emergence of this end product, the release of arachidonic acid by phospholipase A2 enzyme is the triggering event.¹

Leukotrienes are produced from arachidonic acid by the enzyme lipoxygenase, whereas prostaglandins are produced by the enzyme cyclooxygenase (COX). There are 2 isoforms of the COX enzyme. COX-1 isoform is responsible for structural functions such as platelet aggregation, whereas COX-2 is responsible for inflammation increase. COX-2

enzyme provides the formation of prostaglandins, which are the main mediators of inflammation.²⁻⁵ Nonsteroidal anti-inflammatory drugs (NSAIDs) show their anti-inflammatory effects by inhibiting the enzyme COX and prohibiting the formation of prostaglandins.⁶⁻⁸

In the last 20 years, NSAIDs have been commonly used in the treatment of postoperation pain and inflammation after cataract and refractive surgery.⁹ An ideal NSAID should provide a decrease in inflammatory cells and flare in the anterior chamber and a decline in cystoid macular edema in the posterior segment, but it should not have a toxic effect on tissues.¹⁰⁻¹²

For this purpose, new molecules are in the process of being developed. In August 2005, Nevenac was approved by

Departments of ¹Ophthalmology and Vision Sciences and ⁴Pharmaceutical Technology, Faculty of Medicine, Ege University, Izmir, Turkey.

²Department of Ophthalmology and Vision Sciences, Kayseri Training and Research Hospital, Kayseri, Turkey.

³Department of Ophthalmology and Vision Sciences, Central Neftciler Hospital, Baku, Azerbaijan.

⁵Department of Molecular Biology, Faculty of Sciences, Ege University, Izmir, Turkey.

the U.S. FDA to be used in the treatment of pain and inflammation after cataract surgery. Nepafenac is an amid analogue of amfenac.¹³ Nepafenac is a prodrug, and is converted to an active molecule, amfenac, in ocular tissues.¹³ Amfenac inhibits both COX-1 and COX-2 enzymes, thus blocking the formation of prostaglandin. Due to this effect, Nepafenac has been used particularly in the treatment of ocular inflammation and pain that occurs after cataract surgery.^{14–17} The fact that Nepafenac is a prodrug, in contrast to other NSAIDs, makes it favorable. Nepafenac, which is an inactive form that is applied on the eye in drops, is not effective on the applied tissue and does not show any toxicity. After Nepafenac penetrates the cornea, bioactive amfenac is formed by means of iris/ciliary object, choroid/retina.¹³ Thus, its effectiveness is increased whereas side effects are minimized.

Intravitreal drug injection has become indispensable in ophthalmology practice in recent years. This practice that has started with triamcinolone acetonide,^{18–23} has found a frequent field of practice by anti-VEGF preparations.^{24,25} By injecting the drug into a vitreous body, it is thus possible to get to the retina directly, hence more effect is obtained from topical and systemic application.

In our study, the half-life of Nepafenac, which is a molecule proven to be effective in ocular drop form, is measured after intravitreal application, and is investigated by means of electrophysiological, histological, and cytological methods to determine whether it has any toxic effects on the retina.

Methods

The present study conformed to the Association for Research in Vision and Ophthalmology (ARVO) Statement on the Use of Animals in Ophthalmic and Vision Research, and was approved by the Animal Experimentation Ethics Committee of Ege University Committee. Forty Dutch-Belted pigmented rabbits were included in the study.

Experimental procedures

Sterile and iso-osmolar vials were prepared containing Nepafenac active substance in 3, 5, 7.5, and 15 mg/mL concentrations, respectively. Suspensions were prepared by mixing Nepafenac active ingredient with PEG 400 by magnetic mixer, in 5 mL vials. The vials, containing the formulations made into proper particle size, were closed by placing a rubber lid and aluminum caps.

After the vials were closed, they were subjected to radiation sterilization of 5 kGy dose. As the liquid carrier system, sodium carboxymethyl cellulose 0.5% was prepared containing polysorbate 80 of 0.015% and sodium chloride 0.3%. First, a colloidal dispersion of sodium carboxymethyl cellulose was prepared in water for injection, then a formulation of the liquid carrier system was prepared by adding polysorbate 80 and sodium chloride into this system and dissolving them (pH adjusted to 7.5–8.0 with 0.1 N NaOH and/or 0.1 N HCl). The liquid formulation was filled in 5 mL ampoules/vials, and the vials were heat-sealed and exposed to autoclave sterilization. Sterilization was performed at 121°C temperature and 1 atm pressure for 20 min. For sterility control, samples were taken from vials containing Nepafenac suspension and liquid carrier, and plated onto blood agar and Eosin Methylene Blue agar; and at the end of the 48 h incubation period, no microorganisms were detected in the cultures. In the preparation of final solution, formulations with 3,

5, 7.5, and 15 mg/mL concentrations used in animal studies were prepared by adding the carrier liquid into the vials containing Nepafenac suspension, under a laminar air flow cabinet. In the measurements by osmometer, the osmotic pressure of the final solutions was measured to be within the 375–405 mOsmol/kg interval.

The rabbits were split into 4 equal groups, each including 10 rabbits in each group. Before injection, tropicamide (0.5%), phenylephrin (2.5%), and atropine sulfate (1%) were topically administered to experimental animals for pupil dilatation. For topical anesthesia, 5% proparacaine was used. After the application of 5% povidone-iodine, injections were performed in the right eye 2 mm behind the limbus with a 27-gauge needle. 0.1 mL of the formulations of 3, 5, 7.5, and 15 mg/mL concentrations of that containing Nepafenac at 0.3, 0.5, 0.75, and 1.5 mg doses respectively, were applied to 4 groups intravitreally. 0.1 mL saline was injected into left eyes intravitreally, and these eyes were considered as the control group.

Examinations and electrophysiology

Immediately after injection, and at the 1st, 4th, and 8th weeks, anterior segment examination by biomicroscopy, and fundus examination by indirect ophthalmology were performed, and the optical nerves, vascular structures, and retina were evaluated, and intraocular pressure was measured by Schiötz tonometry. In the 4th and 8th weeks after injection, xylazine hydrochloride (20 mg/mL) and ketamine hydrochloride (100 mg/mL) intramuscular analgesia was applied on the rabbits, and full-field electroretinographic (ERG) data were taken under both scotopic and photopic conditions. Experimental animals were subjected to dark adaptation 1 h before measurements, while a monopolar contact lens was placed on the cornea and served as the active electrode; the grounding electrodes were placed on the ipsilateral tragus and the rear left leg. ERG measurements were applied on both eyes simultaneously. Three ERG data were taken for each stimulus. The Metrovision (Vision Monitor; Metrovision Monopack 3, Perenchies, France) system was used for ERG recordings.

Histology

At the end of the 8th week, the rabbits were sacrificed after their eyes were enucleated. Preliminary tests were performed to achieve the best conditions for the eye fixation. For this purpose, 3 different fixation trials were applied:

- right before enucleation 0.2 mL Karnovsky's (1965) fixation liquid at +4°C was injected,
- right before enucleation 0.1 mL Karnovsky's fixation liquid at +4°C was injected, and
- right after enucleation, the eye as a whole was taken into Karnovsky's fixation solution without injecting any fixation solution.

After being preserved overnight at +4°C, the fixated eyes were subjected to second fixation 1% OsO₄ (Millonig). After the series of ethyl alcohol (25%, 50%, 75%, 90%, absolute alcohol), toluene, and epon resin, the eyes were embedded in epoxy resin (epon 812) and polymerized. Cross sections measuring 0.75 μm thick were taken from polymerized blocks and stained with Toluidine blue, and their histological structures were investigated under a light microscope.

TABLE 1. COMPARISON OF THE MEAN RETINA THICKNESS IN THE CONTROL AND APPLICATION GROUPS

| Concentration (mg) | Sample | Total retinal thickness (μm) | | Inner nuclear layer (μm) | | Outer nuclear layer (μm) | |
|--------------------|--------|---|-----------|---------------------------------------|-----------|---------------------------------------|-----------|
| 0.3 | C | 129.3 | $P=0.406$ | 17.6 | $P=0.085$ | 28.3 | $P=0.749$ |
| | A | 136.2 | | 19.1 | | 29.0 | |
| 0.5 | C | 131.6 | $P=1.0$ | 18.1 | $P=1.0$ | 27.4 | $P=0.100$ |
| | A | 132.9 | | 17.9 | | 28.5 | |
| 0.75 | C | 133.1 | $P=0.406$ | 17.8 | $P=0.949$ | 29.3 | $P=0.655$ |
| | A | 136.8 | | 18.2 | | 30.2 | |
| 1.5 | C | 135.3 | $P=0.631$ | 19.3 | $P=0.631$ | 27.8 | $P=0.200$ |
| | A | 142.7 | | 20.7 | | 29.4 | |

$P < 0.05$ was accepted as significant. No difference was observed in any concentration values between control and application eyes when the total retinal thickness and the thickness of the inner nuclear layer and outer nuclear layer were compared.

A, application group; C, control group.

Immediately after the eyes were enucleated, they were divided into 2 in such a way that the parts having the eye lens and the optic nerve would remain in different hemispheres, and placed in vials with Karnovsky's fixation solution to render better fixation. The samples of rabbit eyes, including the drug administered to different groups at different doses, were numbered. The total thickness of the retina, the outer nuclear layer, and the inner nuclear layer were specified as probable parameters where a difference was anticipated between implementation and control groups (Table 1). For this purpose, serial cross sections of 0.75 μm thickness were taken. The cross sections were placed so that there would be 10 on each slide/lame, and measurements were made for the specified parameters in the 10th cross section. Ten slides were prepared for each eye in this way, thus separate measurements were made for 3 segments/regions/areas on 10 cross sections per eye. When a single cross section was taken as the basis, 10 random measurements were made (taking care not to include the oblique parts of the cross section in the measurements) for each segment. Thin cross sections were taken at appropriate places and painted with Uranyl Acetate and Lead Citrate, then investigated in a Jeol 100C transmission electron microscope, and micrographs were taken.

Statistics

The data collected were evaluated using the Mann-Whitney U-test for the differences between control and application groups by using the SPSS statistical software. The P value < 0.05 was accepted for statistical significance.

Results

Clinical observations

No abnormal or unusual findings were observed in any of the rabbits, either in the anterior or posterior segment examinations. There were no significant differences with regard to the intraocular pressure in the timeline between the eyes of the study and control groups (Table 2).

ERG findings

In ERG measurements, a and b wave amplitudes as well as flicker response amplitudes, in both scotopic and photopic measurements, were evaluated. Similar wave forms were obtained from all the eyes, whether injected or not. Also, the values obtained in amplitude measurements were similar.

The graphs obtained by taking the average values into consideration are seen in Figure 1. However, since the number of samples was too small, statistical significance could not be evaluated.

Histology

The results obtained at the end of preliminary trials were compared, and according to the specified parameters, the best results were taken with the samples treated just before enucleation with 0.1 mL Karnovsky's fixation solution liquid at $+4^\circ\text{C}$.

In the comparative examination of application and control samples with respect to each other by taking cross sections from the retinal layer, no histologically apparent difference was observed in different concentration groups (Figs. 2-4).

No significant difference was detected in the histological cross sections of the eyes in the control and application groups of 1.5 mg dose group where the dose was maximized. Only a minimal difference was detected in the cross sections of the sample number 15.5. In both of the control (C.15.5) and application (A.15.5) samples, all retinal layers were clearly distinguished. It was understood from the rod-shaped cells that the cross section of the control sample were slightly oblique. However, in the application sample,

TABLE 2. INTRAOCULAR PRESSURE MEASUREMENTS IN THE CONTROL AND APPLICATION GROUPS

| Dose | Before injection | | | | |
|---------|------------------|------------------|------------------|------------------|------------------|
| | 1 day | 1 week | 1 month | | |
| 0.3 mg | R | 17.02 \pm 1.65 | 18.04 \pm 1.42 | 16.63 \pm 1.85 | 18.82 \pm 2.01 |
| | L | 18.52 \pm 2.04 | 15.22 \pm 1.69 | 19.28 \pm 1.64 | 19.02 \pm 1.23 |
| 0.5 mg | R | 16.35 \pm 1.94 | 18.15 \pm 1.32 | 17.36 \pm 1.63 | 15.26 \pm 1.62 |
| | L | 15.48 \pm 2.44 | 17.64 \pm 1.84 | 18.05 \pm 1.86 | 16.34 \pm 2.01 |
| 0.75 mg | R | 19.21 \pm 1.22 | 18.62 \pm 1.48 | 19.65 \pm 2.12 | 20.04 \pm 1.35 |
| | L | 18.86 \pm 1.95 | 18.52 \pm 1.47 | 17.22 \pm 1.14 | 18.04 \pm 1.69 |
| 1.5 mg | R | 16.23 \pm 1.28 | 15.26 \pm 1.65 | 14.79 \pm 1.29 | 15.94 \pm 1.27 |
| | L | 17.42 \pm 1.64 | 17.58 \pm 1.37 | 16.84 \pm 1.51 | 18.17 \pm 1.92 |

1 day, 1 day after injection; 1 week, 1 week after injection; 1 month, 1 month after injection; L, left eye; R, right eye.

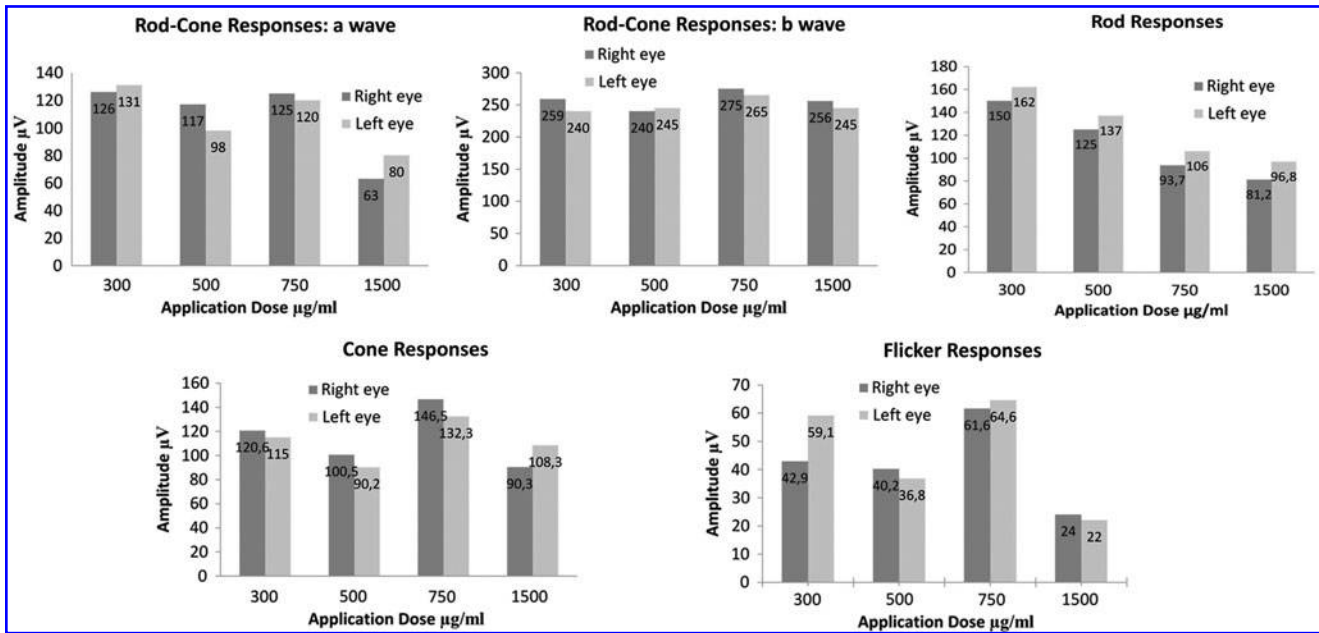


FIG. 1. Electoretinographic responses of the right and left eyes.

longitudinal sections of the rod-shaped cells could be clearly distinguished. The obvious difference was the wide spaces observed in the inner nuclear and ganglion cell layer of the application sample. As for this view, it would not be wrong to say that there was some decrease in the number of ganglion cells and inner nuclear layer cells. This is the only pair in this group with any noticeable difference (Fig. 5).

The cross sections taken during histological observations, to determine the total thickness of outer nuclear layers, inner nuclear layers, and retinal layers of both control and application samples, were placed in such a way that there would be 10 in each slide, and measurements were made for the specified parameters on the 10th cross section. This way, 10

slides were prepared for each eye and separate measurements for 3 areas out of 10 cross sections per eye. When 1 single cross section was taken as a basis, 10 random measurements were made for each area. Therefore, for each of the 3 parameters, a total of 100 measurements were made providing 300 measurements per eye. The data were then statistically analyzed (Table 1).

Cytological findings

At the end of the histological investigations, electron microscopic investigations were performed. The cross

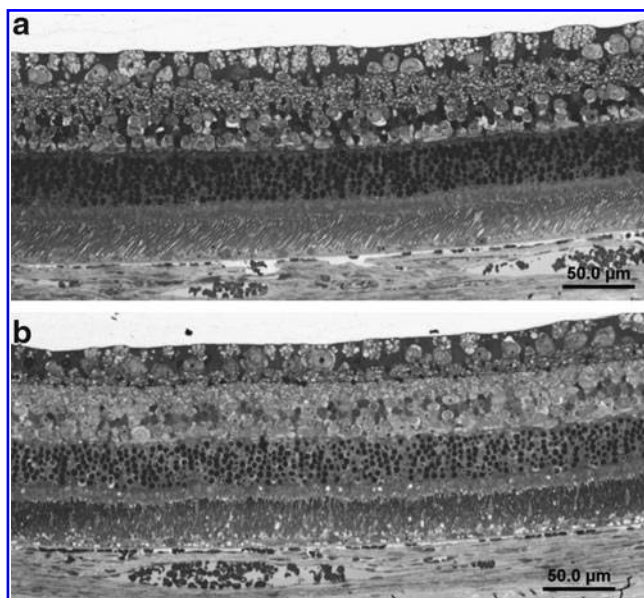


FIG. 2. Cross sections taken from samples of (a) control (C.3.6) and (b) 0.3 mg drug injected (A.3.6). Semi-thin Epon 812 cross section.

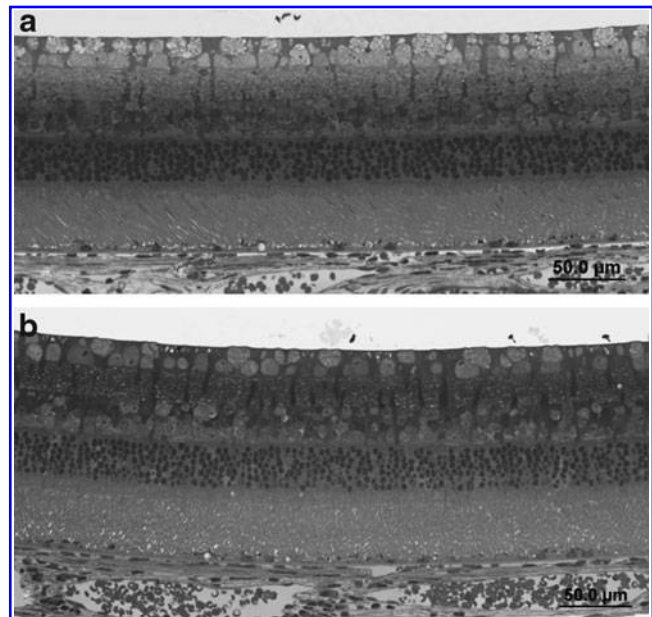


FIG. 3. Cross sections taken from samples of (a) control (C.5.3) and (b) 0.5 mg drug injected (A.5.3). Semi-thin Epon 812 cross section.

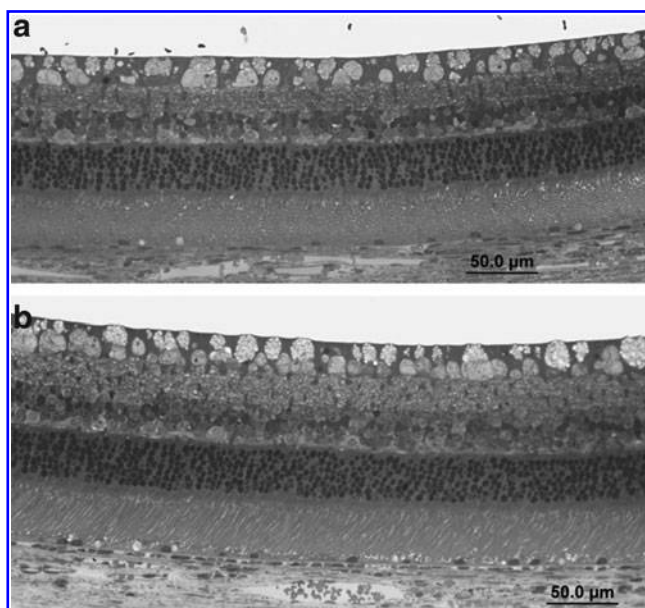


FIG. 4. Cross sections taken from samples of (a) control (C.7.1) and (b) 0.75 mg drug injected (A.7.1). Semi-thin Epon 812 cross section.

sections of the A.15.5 sample, where maximum difference was observed at the highest dose, are presented below. A relationship between retinal epithelial cells and photoreceptor cells was observed in the application sample of code A.15.5. Plenty of large pigment granules could be seen in the retinal epithelium, and right underneath them, there was a circular structure (drusen), which resembled the cell nucleus at first sight, but it was understood that was not the nucleus. Right outside the retinal cell membrane that follow pigment granules, were the oblique cross sections of the external segment extensions of photoreceptor (conical and rod-shaped) cells. In the thin cross sections of the external segment of the application sample coded A.15.5, horizontal and longitudinal cuts of the segments displayed irregular-

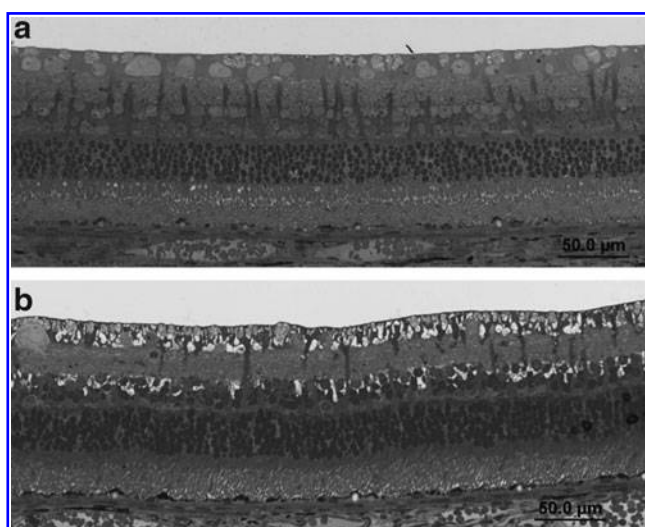


FIG. 5. Cross sections taken from samples of (a) control (C.15.5) and (b) 1.5 mg drug injected (A.15.5). Semi-thin Epon 812 cross section.

ities in the membrane foldings, whereas some were clear, some not. Besides, mitochondria could be distinguished inside the segments. The cell nucleus could be seen on the thin cross sections taken from the inner nuclear layer of the application sample coded A.15.5. While some nuclei appeared to be normal in terms of general structure, membrane breakdowns and degradations were remarkable in some others. Some of the deformed and swollen mitochondria showed a close relationship with the nuclei. Furthermore, in the bottom side of the image, cell waste dump drew attention (Figs. 6–8), although this finding was not associated with any ocular deficits based on ERG.

Discussion

Corticosteroids are effective agents used in the treatment of various inflammatory ocular pathologies. These drugs are also for intravitreal use,^{18–23} but due to well-known side effects of the intraocular steroids, these treatments cannot be used on some patients.^{26–46} There is a need for alternative treatment methods to corticosteroids. In this study, we have investigated the intraocular reliability of Nepafenac, which is a nonsteroidal anti-inflammatory agent that could be an effective alternative to corticosteroids.

Topical Nepafenac 0.1% (1 mg/mL) suspension was approved in 2005, and 0.3% (3 mg/mL) suspension was approved in 2012.⁴⁷ Although Nepafenac was not approved for intravitreal use, we applied this drug intravitreally. The lowest concentration in our study was the effective dose (3 mg/mL=0.3 mg). In other words, we evaluated the effective dose and higher levels than the effective dose (including 0.3, 0.5, 0.75, and 1.5 mg doses) of Nepafenac delivered intravitreally. On the anterior and posterior segment examinations, we did not detect any pathological findings or intraocular pressure differences in the eyes administered with the effective and higher doses of this drug. When ERG findings were examined for each rabbit eye where a different dose was applied, the amplitude was observed to be measured as the same, minimally less or minimally more in the application eyes compared to control eyes, and these changes are not thought to be interpreted in favor of toxicity.

In the comparison for control and application samples, the histologically most significant difference was in the sample coded A.15.5, which included spaces in the ganglion cell

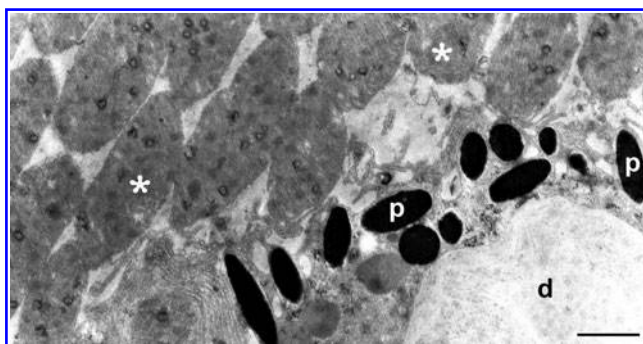


FIG. 6. The relation between retinal epithelium and photoreceptor cells in 1 application sample A.15.5. p, retinal pigment; d, drusen; *, outer segment extensions of the photoreceptor cells. Uranyl acetate and lead citrate, scale bar: 1 µm.

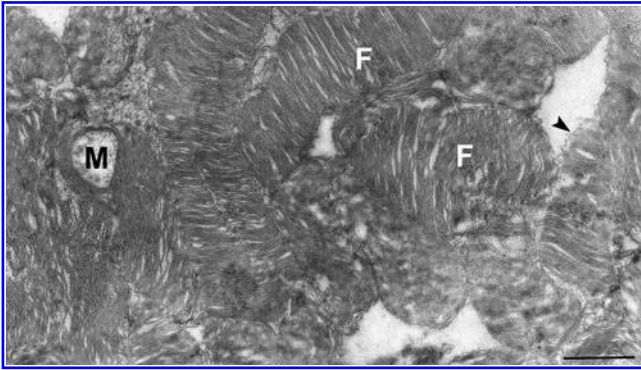


FIG. 7. Outer segment parts of photoreceptor cells in the application sample A.15.5. F, membrane folds on the outer segment of photoreceptor cells; ►, the fields with indistinct membranes in the outer segment parts; M, mitochondria. Uranyl acetate and lead citrate, scale bar: 1 μ m.

and inner nuclear layers, which were not present in the control (C.15.5). It is thought that the reason for these spaces may be due to the decrease in the number of cells. However, this finding was not associated with any ocular deficits based on ERG in the sample coded A.15.5; we have not discovered such findings in any other preparations where high dose of drugs were applied; and no significant difference was detected in the statistical measurements of the average retina thickness in this group. No remarkable difference was detected histologically in the other samples. In summation, from a histological point of view, a notable difference was not observed between the application and control samples.

In the measurement of thickness of different retinal layers (outer nuclear, inner nuclear) and its total retinal thickness, a statistically significant difference was not observed even in the highest concentration group. However, it was observed that the outer nuclear layer was thicker in the application group in all concentration groups. The reason we were unable to determine any significance may be due to the rather low number of samples.

The cross sections taken from the different layers of retina for electron microscopic investigations were inspected at a certain sequence and micrographs were taken. In the region from inner segments of photoreceptors to ganglion cells, no histological abnormality was detected. In the electron

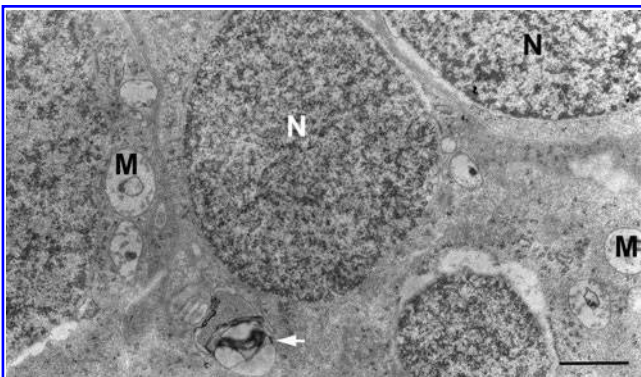


FIG. 8. Inner nuclear layer in the application sample A.15.5. N, nucleus; M, mitochondria; ►, cellular waste. Uranyl acetate and lead citrate, scale bar: 1 μ m.

micrographs in general, no image indicating a heavy pathology was encountered. The most apparent image was in the preparation coded 15.5, where 1.5 mg of the drug was applied as the occurrence of swollen mitochondria and deformation of the cristae. In some cases, however, local deformations were observed in both nucleus and some photoreceptor outer segment membrane structures. Considering that a typical indication of an imperfect fixation would be deformations on membrane structures and swelling of mitochondria, it may be possible that such observed findings are due to poor fixation.

In previous studies, ocular toxicity of intraocular application of other nonsteroid molecules, such as flurbiprofen, diclofenac vs. ketorolac, was investigated in electrophysiological and histological studies.^{48–50} Shen et al.,⁴⁸ following intravitreal gas and vitrectomy application on 26 rabbit eyes, applied diclofenac at various concentrations between 100 and 1,080 μ g/mL and did not determine any finding of toxicity up to 400 μ g/mL. In concentrations over 400 μ g/mL, however, they had histologically specified retinal toxicity in addition to macroscopic toxicity findings, such as cataract, vitreous haze, and gray–white view on retina. Histological toxicity findings were observed at optical microscopy as retinal thinning, detached retina pigment epithelium (RPE), and losses in photoreceptor outer segments and nuclei; whereas this appeared at electron microscopy as large vacuoles and pigment granule accumulations in RPE and irregularities in photoreceptor outer segments and photoreceptor nucleus necrosis.

Shimada et al.,⁴⁹ used flurbiprofen active substance, applied at 4 and 40 μ g/mL, on 12 macaque monkeys after vitrectomy in various concentrations, and could not determine any toxicity below doses of 1,000 μ g/mL. However, they concluded that it was toxic above 1,000 μ g/mL concentrations. Margalit et al.,⁵⁰ determined electrophysiologically and histologically that an intravitreal application of 0.1 mL solution of 0.5% ve 0.25% ketorolac trimethylene active substance on rabbit eyes was not toxic.

In our study, we have not macroscopically encountered any toxicity by the intravitreal application of Nepafenac, which is a new NSAID prodrug, nor have we determined any histological irregularities. We have not specified any change electrophysiologically with respect to control eyes.

In conclusion, our data show that intravitreal application of 0.3, 0.5, 0.75, and 1.5 mg doses of Nepafenac active substance is nontoxic to the rabbit retina. It is probable that Nepafenac may be used as an agent applicable in treatment of various retina diseases in the future.

Acknowledgments

Support for this study was provided by the Ege University Research Foundation.

Author Disclosure Statement

No competing financial interests exist. No author has a financial or proprietary interest in any material or method mentioned.

References

1. Kudo, I., and Murakami, M. Phospholipase A2 enzymes. *Prostaglandins Other Lipid Mediat.* 68–69:3–58, 2002.

2. Ueno, N., Murakami, M., Tanioka, T., et al. Coupling between cyclooxygenase, terminal prostanoid synthase, and phospholipase A2. *J. Biol. Chem.* 276:34918–34927, 2001.
3. Shen, R.F., and Tai, H.H. Thromboxanes: synthase and receptors. *J. Biomed. Sci.* 5:153–172, 1998.
4. Helliwell, R.J., Adams, L.F., and Mitchell, M.D. Prostaglandin synthases: recent developments and a novel hypothesis. *Prostaglandins Leukot. Essent. Fatty Acids.* 70:101–113, 2004.
5. Ruan, K.H., and Dogne, J.M. Implications of the molecular basis of prostacyclin biosynthesis and signaling in pharmaceutical designs. *Curr. Pharm. Des.* 12:925–941, 2006.
6. Vane, J.R. The mode of action of aspirin and similar compounds. *J. Allergy Clin. Immunol.* 58:691–712, 1976.
7. Vane, J.R., Bakhle, Y.S., and Botting, R.M. Cyclooxygenases 1 and 2. *Annu. Rev. Pharmacol. Toxicol.* 38:97–120, 1998.
8. Botting, R.M. Inhibitors of cyclooxygenases: mechanisms, selectivity and uses. *J. Physiol. Pharmacol.* 57:113–124, 2006.
9. Gaynes, B.I., and Fiscella, R. Topical nonsteroidal anti-inflammatory drugs for ophthalmic use: a safety review. *Drug Saf.* 25:233–250, 2002.
10. Sivaprasad, S., Bunce, C., and Wormald, R. Non-steroidal anti-inflammatory agents for cystoid macular oedema following cataract surgery: a systematic review. *Br. J. Ophthalmol.* 89:1420–1422, 2005.
11. Yilmaz, T., Cordero-Coma, M., and Gallagher, M.J. Ketorolac therapy for the prevention of acute pseudophakic cystoid macular edema: a systematic review. *Eye (Lond).* 26:252–258, 2012.
12. Weber, M., Kodjikian, L., Kruse, F.E., Zagorski, Z., and Allaire, C.M. Efficacy and safety of indomethacin 0.1% eye drops compared with ketorolac 0.5% eye drops in the management of ocular inflammation after cataract surgery. *Acta Ophthalmol.* 91:15–21, 2013.
13. Lane, S.S. Nepafenac: a unique nonsteroidal prodrug. *Int. Ophthalmol. Clin.* 46:13–20, 2006.
14. Gamache, D.A., Graff, G., Brady, M.T., et al. Nepafenac, a unique nonsteroidal prodrug with potential utility in the treatment of trauma-induced ocular inflammation: I. Assessment of anti-inflammatory efficacy. *Inflammation.* 24:357–370, 2000.
15. Ke, T.L., Graff, G., Spellman, J.M., and Yanni, J.M. Nepafenac, a unique nonsteroidal prodrug with potential utility in the treatment of trauma-induced ocular inflammation: II. *In vitro* bioactivation and permeation of external ocular barriers. *Inflammation.* 24:371–384, 2000.
16. Kapin, M.A., Yanni, J.M., Brady, M.T., et al. Inflammation-mediated retinal edema in the rabbit is inhibited by topical nepafenac. *Inflammation.* 27:281–291, 2003.
17. Lane, S.S., Modi, S.S., Lehmann, R.P., et al. Nepafenac ophthalmic suspension 0.1% for the prevention and treatment of ocular inflammation associated with cataract surgery. *J. Cataract Refract. Surg.* 33:53–58, 2007.
18. Penfold, P., Gyory, J., Hunyor, A., et al. Exudative macular degeneration and intravitreal triamcinolone. A pilot study. *Aust. N. Z. J. Ophthalmol.* 23:293–298, 1995.
19. Challa, J.K., Gillies, M.C., Penfold, P.L., et al. Exudative macular degeneration and intravitreal triamcinolone: 18 month follow up. *Aust. N. Z. J. Ophthalmol.* 26:277–281, 1998.
20. Danis, R., Ciulla, T., Pratt, L., et al. Intravitreal triamcinolone acetonide in exudative macular degeneration. *Retina.* 20:244–250, 2000.
21. Jonas, J.B., Hayler, J.K., and Panda-Jonas, S. Intravitreal injection of crystalline cortisone as adjunctive treatment of proliferative vitreoretinopathy. *Br. J. Ophthalmol.* 84:1064–1067, 2000.
22. Cekic, O., Chang, S., Tseng, J.J., Barile, G.R., Del Priore, L.V., Weissman, H., et al. Intravitreal triamcinolone injection for treatment of macular edema secondary to branch retinal vein occlusion. *Retina.* 25:851–855, 2005.
23. Lee, H., and Shah, G.K. Intravitreal triamcinolone as primary treatment of cystoids macular edema secondary to branch retinal vein occlusion. *Retina.* 25:551–555, 2005.
24. Eyetech Study Group. Anti-vascular endothelial growth factor therapy for subfoveal choroidal neovascularization secondary to age-related macular degeneration: phase II study results. *Ophthalmology.* 110:979–986, 2003.
25. Heier, J.S., Antoszyk, A.N., Pavan, P.R., et al. Ranibizumab for treatment of neovascular age-related macular degeneration: a phase I/II multicenter, controlled, multidose study. *Ophthalmology.* 113:633.e1–e4, 2006.
26. Jonas, J.B., Kreissig, I., and Degenring, R.F. Endophthalmitis after intravitreal injection of triamcinolone acetonide. *Arch. Ophthalmol.* 121:1663–1664, 2003.
27. Jonas, J.B., Kreissig, I., Spandau, U.H., and Harder, B. Infectious and noninfectious endophthalmitis after intravitreal high-dosage triamcinolone acetonide. *Am. J. Ophthalmol.* 141:579–580, 2006.
28. Nelson, M.L., Tennant, M.T., Sivalingam, A., et al. Infectious and presumed noninfectious endophthalmitis after intravitreal triamcinolone acetonide injection. *Retina.* 23:686–691, 2003.
29. Parke, D.W. Intravitreal triamcinolone and endophthalmitis. *Am. J. Ophthalmol.* 136:918–919, 2003.
30. Bakri, S.J., and Beer, P.M. The effect of intravitreal triamcinolone acetonide on intraocular pressure. *Ophthalmic Surg Lasers Imaging.* 34:386–390, 2003.
31. Chan, C.K., Fan, D.S., Chan, W.M., et al. Ocular hypertensive response and corneal endothelial changes after intravitreal triamcinolone injections in Chinese subjects: a 6-month follow-up study. *Eye (Lond).* 19:625–630, 2005.
32. Jonas, J.B., Degenring, R.F., Kreissig, I., Akkoyun, I., and Kampeter, B.A. Intraocular pressure elevation after intravitreal triamcinolone acetonide injection. *Ophthalmology.* 112:593–598, 2005.
33. Jonas, J.B., Kreissig, I., and Degenring, R. Secondary chronic open-angle glaucoma after intravitreal triamcinolone acetonide. *Arch. Ophthalmol.* 121:729–730, 2003.
34. Park, H.Y., Yi, K., and Kim, H.K. Intraocular pressure elevation after intravitreal triamcinolone acetonide injection. *Korean J. Ophthalmol.* 19:122–127, 2005.
35. Razeghinejad, M.R., and Katz, L.J. Steroid-induced iatrogenic glaucoma. *Ophthalmic Res.* 47:66–80, 2012.
36. Sampat, K.M., and Garg, S.J. Complications of intravitreal injections. *Curr. Opin. Ophthalmol.* 21:178–183, 2010.
37. Jaissle, G.B., Szurman, P., and Bartz-Schmidt, K.U. Ocular side effects and complications of intravitreal triamcinolone acetonide injection (in German). *Ophthalmologe.* 101:121–128, 2004.
38. Cekic, O., Chang, S., Tseng, J.J., et al. Cataract progression after intravitreal triamcinolone injection. *Am. J. Ophthalmol.* 139:993–998, 2005.
39. Özkiris, A., and Erkiliç, K. Complications of intravitreal injection of triamcinolone acetonide. *Can. J. Ophthalmol.* 40:63–68, 2005.
40. Jonas, J.B., Degenring, R., Vossmerbauemer, U., and Kampeter, B. Frequency of cataract surgery after intravitreal injection of high-dosage triamcinolone acetonide. *Eur. J. Ophthalmol.* 15:462–464, 2005.

41. Bouzas, E.A., Karadimas, P., and Pournaras, C.J. Central serous chorioretinopathy and glucocorticoids. *Surv. Ophthalmol.* 47:431–448, 2002.
42. Macky, T.A., Helmy, D., and El Shazly, N. Retinal toxicity of triamcinolone's vehicle (benzyl alcohol): an electrophysiologic and electron microscopic study. *Graefes Arch. Clin. Exp. Ophthalmol.* 245:817–824, 2007.
43. Torriglia, A., Valamanesh, F., and Behar-Cohen, F. On the retinal toxicity of intraocular glucocorticoids. *Biochem. Pharmacol.* 80:1878–1886, 2010.
44. Lang, Y., Zemel, E., Miller, B., and Perlman, I. Retinal toxicity of intravitreal Kenalog in albino rabbits. *Retina.* 27:778–788, 2007.
45. Tokuda, K., Tsukamoto, T., Fujisawa, S., and Matsubara, M. Evaluation of toxicity due to vital stains in isolated rat retinas. *Acta Ophthalmol. Scand.* 82:189–194, 2004.
46. Tao, Y., and Jonas, J.B. Intravitreal triamcinolone. *Ophthalmologica.* 225:1–20, 2011.
47. Jones, B.M., and Neville, M.W. Nepafenac: an ophthalmic nonsteroidal antiinflammatory drug for pain after cataract surgery. *Ann. Pharmacother.* 47:892–896, 2013.
48. Shen, W.Y., Constable, I.J., Chelva, E., and Rakoczy, P.E. Inhibition of diclofenac formulated in hyaluronan on angiogenesis *in vitro* and its intraocular tolerance in the rabbit eye. *Graefes Arch. Clin. Exp. Ophthalmol.* 238:273–282, 2000.
49. Shimada, H., Kawamura, A., Shingyouchi, S., Shingyouchi, F., and Matsui, M. Effects of an anti-prostaglandin agent added to the irrigation solution on damage to the anterior segment in monkey eyes induced by pars plana vitrectomy. *Nihon Ganka Gakkai Zasshi.* 93:823–829, 1989.
50. Margalit, E., Kugler, L.J., Brumm, M.V., et al. The safety of intraocular ketorolac in rabbits. *Invest. Ophthalmol. Vis. Sci.* 47:2093–2099, 2006.

Received: June 11, 2014

Accepted: August 26, 2014

Address correspondence to:

Dr. Arzu Seyhan Karatepe Hashas
Department of Ophthalmology and Vision Sciences
Kayseri Training and Research Hospital
Kayseri 38010
Turkey

E-mail: arzuskaratepe@hotmail.com